

CLINICAL AND HEMATOLOGICAL ASPECTS OF DOGS NATURALLY INFECTED WITH *Ehrlichia* spp. AND *Leptospira interrogans*

ASPECTOS CLÍNICOS E HEMATOLÓGICOS DE CÃES NATURALMENTE INFECTADOS COM *Ehrlichia* spp. E *Leptospira interrogans*

Naiari do Carmo MORAIS¹; Jacqueline Ribeiro de CASTRO¹; Antonio Vicente MUNDIM²; José Eugênio Diniz BASTOS³; Fernando Antônio FERREIRA³; Mariana Assunção SOUZA¹; Sandra Renata Sampaio SALABERRY¹; Anna Monteiro Correia LIMA-RIBEIRO¹

1. Laboratory of Contagious Infectious Diseases, Faculty of Veterinary Medicine, of the Federal University of Uberlândia, Uberlândia, MG, Brazil. jack_ufu@hotmail.com.br; 2. Laboratory of Clinical Pathology, Veterinary Hospital, of the UFU, Uberlândia, MG, Brazil; 3. Medical Clinic, Faculty of Veterinary Medicine of the UFU, Uberlândia, MG, Brazil.

ABSTRACT: Ehrlichiosis and leptospirosis are frequent diseases in tropical countries, although they are not always considered as differential diagnosis. The purpose of this work was to evaluate clinical signs and hematological alterations in dogs reactive to leptospirosis, among them those that presented morulae of *Ehrlichia* spp. in peripheral blood, and to recognize the frequency of *Leptospira* serovars by means of the microscopic agglutination test. Blood samples were used from 50 dogs presenting morulae of *Ehrlichia* spp. in blood extensions collected from the ear marginal capillaries. The clinical signs frequently observed were apathy (100.00%), anorexia/dysorexia (100.00%), adypsia (83.33%), ocular secretion (66.66%), reactive lymph nodes (66.66%), diarrhea (58.33%), vomiting, anemia and fever (41.66%). Albeit unspecific, anemia and thrombocytopenia are frequent hematological findings in canine ehrlichiosis and are present in both diseases. Of the 50 dogs with ehrlichiosis, 12 (24.00%) were reactive to leptospirosis, and the most frequent serovars were Pomona (33.33%), followed by Canicola (27.77%) and Icterohaemorrhagiae (22.22%). The results suggest the need to establish a differential diagnosis between these diseases that may occur concomitantly.

KEYWORDS: *Canis familiaris*. Ehrlichiosis. Hematology. Leptospirosis.

INTRODUCTION

The canine population's growth has been favored by urbanization and by social changes in the population (SOUZA et al., 2002). Hence, dogs participate effectively in the epidemiological chain of a variety of zoonosis since they are pets that have close contacts with humans (BRASIL, 2002).

Ehrlichiosis, which is considered a zoonosis, is caused by an obligate intracellular parasite. Several species of ehrlichia can contaminate dogs, including *Ehrlichia canis* – the agent of canine monocytic ehrlichiosis, *Ehrlichia chaffeensis* – the agent of human monocytic ehrlichiosis, and *Ehrlichia ewingii* – the agent of canine granulocytic ehrlichiosis (DAGNONE et al., 2001; DUMLER et al., 2001).

In Brazil, *E. canis* is imputed to be responsible for the most pathogenic canine monocytic ehrlichiosis frequently associated with the clinical disease (LAPPIN, 2010). The disease is considered endemic, mainly in urban areas, where there is an abundant occurrence of populations of the vector tick, *Rhipicephalus sanguineus* (LABRUNA; PEREIRA, 2001). In the state of Minas Gerais, the disease was reported in dogs for

the first time in the city of Belo Horizonte (COSTA et al., 1973).

The diagnosis can be made based on the detection of intracellular clusters of the microorganism contained within a membrane, called morulae, which are present in the leukocytes in peripheral blood smears during the acute phase (STILES, 2000) or by means of serology using Indirect Immunofluorescence, ELISA or PCR techniques, and by isolation and culture (ANDEREG; PASSOS, 1999). Serology and nested PCR are suitable assays for the confirmation of canine ehrlichiosis, but they should complement clinical and hematological exams (CONH, 2003; NAKAGHI et al., 2008). Therefore, serology is important in the phases in which there is no parasitemia, and also allows for the identification of the species involved.

Visualization of morulae in peripheral blood provides a definitive diagnosis, but it is a slow process that also yields many false-negative results. Although it is corroborative, the hematozoon examination is severely limited by its low sensitivity, since it may be difficult to observe corpuscles and morulae in the subacute and chronic phases due to low parasitemia, thus making it

advisable to use other diagnostic methods (MOREIRA et al., 2005).

Another important zoonosis is leptospirosis whose easy transmission leads to high morbidity according to public health warnings. Among domestic animals in urban areas, dogs are the main source of infection for humans because of their direct contact and the fact that they can asymptotically eliminate live leptospirae in their urine for several months (MAGALHÃES et al. 2006; ADLER; MOCTEZUMA, 2010).

The diagnosis is based on clinical and epidemiological information, confirmed by laboratorial exams, and the microscopic agglutination test with live antigens is recommended by the World Health Organization (WHO, 2003).

Routine exams at the Federal University of Uberlândia Veterinary Teaching Hospital of the College of Veterinary Medicine show frequent diagnosis of animals with ehrlichiosis. However, the clinical diagnosis confirmed by the detection of morulae in peripheral blood smears interrupts the search for other etiological agents that may be present in the clinical picture under evaluation.

The lack of a differential diagnosis due to similar clinical factors leads to inadequate treatment, since it does not eliminate the renal carrier stage of *Leptospira* spp. In view of this concern and the possibility of other diseases affecting an animal at the same time, it was decided to verify the occurrence of animals reactive to leptospirosis among those testing positive for ehrlichiosis.

The aim was to evaluate clinical signs and hematological abnormalities in dogs reactive to *Leptospira* spp. among those that presented *Ehrlichia* spp. morulae in peripheral blood. Another aim was to ascertain the frequency of *Leptospira* serovars by means of the Microscopic Agglutination Test (MAT).

MATERIAL AND METHODS

The study involved 50 dogs of both sexes, of various breeds and ages, treated at the Veterinary Teaching Hospital of the Federal University of Uberlândia, MG, Brazil from November 2007 to April 2008. These animals, which had not previously received any kind of treatment, presented morulae of *Ehrlichia* spp. in blood samples drawn from the ear marginal capillaries. The blood smears were stained by the May-Grünwald Giemsa (FELDMAN et al., 2000) method and were used for a study of hemoparasites and a differential leukocyte count.

The clinical signs of all the dogs were evaluated according to the animal's clinical chart tracked by the number of its medical record.

After antiseptics with alcohol iodine, 5 mL of blood were collected from the accessory cephalic or external jugular vein, using 5 mL syringes and disposable 25x7 needles for the hemogram. Two mL of blood were then transferred to a silicone coated vacutainer tube containing anticoagulant (0.1 mL of 10% EDTA – ethylene-diamine-tetra-acetic acid), and 3 mL were placed in a tube without anticoagulant for serum extraction.

The hemograms were performed at the Laboratory of Clinical Pathology of the Veterinary Teaching Hospital of FAMEV, UFU, by the electronic method, using an ABC VET[®] animal blood counter. The tubes containing blood samples without anticoagulant were sent to the Laboratory of Contagious Infectious Diseases of the same institution for the leptospirosis serum screening test. The samples were centrifuged at 2,500 rpm for 5 min. The serum was then extracted with a micropipette and transferred to conical-bottom polypropylene tubes, which were stored at -20°C until the moment of the exam.

The diagnostic method adopted for the serology of leptospirosis was MAT, considered the golden standard, which detects serum antibodies starting seven days after infection (BRASIL, 1995; LABRUNA; PEREIRA, 2001). The serovars tested were Hardjo, Canicola, Pomona, Wolffi, Icterohaemorrhagiae, Grippityphosa and Pyrogenes. Antigens were prepared from matrices transplanted weekly in a STUART (Difco[®]) culture medium enriched with 10% rabbit serum, stored in an incubator at 30°C and used close to the sixth day of incubation.

The coefficient of prevalence of the animals testing positive for leptospirosis was determined, as was the most frequent serovar and the clinical signs with the highest occurrence (THRUSFIELD, 2004). The results were analyzed by descriptive statistics, using Student's parametric test for two independent samples (*t* test) with a 5% level of significance, for the comparison of two means according to Ayres et al. (2007).

The research was developed according to the standards established by the institution's ethics committee (015/08).

RESULTS

Among the 50 samples containing morulae of *Ehrlichia* spp. in their peripheral smears, 12 were

reactive to leptospirosis in the MAT test, resulting in a prevalence of 24.00%.

The frequencies of serovars showed 33.33% of dogs reactive to the serovar Pomona, 27.77% positive for Canicola, 22.22% for Icterohaemorrhagiae, 11.11% for Wolffi and 5.55% for Hardjo. No animals were found to be serum

reactive to the serovars Pyrogenes and Grippotyphosa. Coagglutination occurred when the same dog was reactive to more than one serovar.

The main hematological alterations of the 50 dogs with ehrlichiosis were anemia and thrombocytopenia, as Table 1.

Table 1. Mean, standard deviation, and amplitude of variation of the hematological parameters of 50 domestic dogs naturally infected with *Ehrlichia* spp. and treated at the Veterinary Teaching Hospital of the Federal University of Uberlândia, MG, Brazil, 2008.

Parameters evaluated	Mean	Standard deviation	Minimum	Maximum	Reference values*
Hematocrit %	29.04	11.23	7.70	57.20	37-55
Erythrocytes x 10 ⁶ /µL	4.52	1.71	1.04	8.25	5.5-8.5
Hemoglobin g/dL	9.45	3.77	2.50	20.00	12-18
Platelets /µL	108,222	96,795	14,000	443,000	200,000-500,000
Leukocytes /µL	9,008	6,484	1,500	41,200	6,000-17,000
Segmented neutrophils /µL	4,971	3,923	285	24,720	3,000-11,500
Lymphocytes /µL	2,168	10,604	261	10,604	1,000-4,800
Monocytes /µL	739	883	112	5,061	150-1,350
Basophils /µL	0	0	0	0	Rare

* Meinkoth; Clinkenbeard (2000).

In this study, it was possible to compare the mean hematological values of the dogs infected only with *Ehrlichia* spp. against those infected with both

Ehrlichia spp. and *Leptospira interrogans* (Table 2).

Figure 1 describes the complaints and clinical signs found in the dogs.

Table 2. Comparison of the mean hematological values of dogs naturally infected only with *Ehrlichia* spp. and those infected with *Ehrlichia* spp. and *Leptospira interrogans*.

Parameters evaluated	Mean values		Reference values*
	<i>Ehrlichia</i> spp.	<i>Ehrlichia</i> spp.+ <i>L. interrogans</i>	
Hematocrit %	30.39a	24.82b	37-55
Erythrocytes x 10 ⁶ /µL	4.73a	3.87b	5.5-8.5
Hemoglobin g/dL	9.88a	8.07b	12-18
Platelets /µL	102,107a	127,583b	200,000-500,000
Leukocytes /µL	8,434a	10,825b	6,000-17,000
Segmented neutrophils /µL	4,620a	6,083b	3,000-11,500
Lymphocytes /µL	2,037a	2,580a	1,000-4,800
Monocytes /µL	663a	981a	150-1,350
Basophils /µL	0	0	Rare

*Meinkoth; Clinkenbeard (2000); (a; b) different letters on the same line indicate statistically different means (p<0.05).

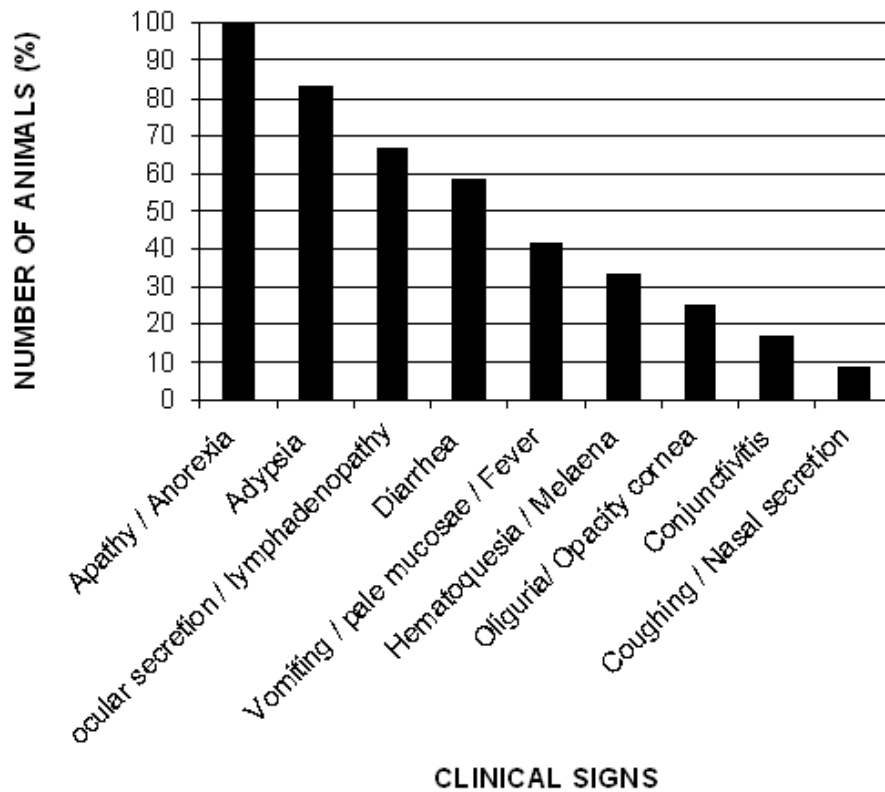


Figure 1. Clinical signs presented by dogs infected naturally with *Ehrlichia* spp. and *Leptospira interrogans*

DISCUSSION

Ehrlichiosis and leptospirosis can occur simultaneously in the same host without being properly diagnosed, because ehrlichiosis is an opportunistic agent that develops when the immunological system is imbalanced. In addition to being immunosuppressant, ehrlichiosis can trigger medullary aplasia and drastically reduce the defense cells, thus allowing the installation of other pathogens such as *Leptospira interrogans*.

Of the 50 dogs evaluated in this study, 12 were MAT reactive. The prevalence of leptospirosis (24.00%) should not be compared with that found by other researchers because no similar evaluation was found in the literature, since the methodologies employed were different.

The frequencies of serovars found were differed from those reported by other authors (FURTADO et al., 1997; ÁVILA et al., 1998; ALVES et al., 2000), who found serum prevalence for Autumnalis, Butembo, Grippotyphosa, Australis, Canicola and Icterohaemorrhagiae. Infecting serovars depend of the assessed species, the contactant animals, the region evaluated, the presence of hosts, and maintenance of the agent in the environment, and there may be differences of

serum prevalence in evaluated locations (FURTADO et al., 1997).

The high occurrence of the serovar Canicola confirms that dogs are an important source of contamination for humans because they are the main host of this serovar, which adapts easily to the canine renal tissue and can be eliminated for long periods after infection. The discovery of serovars not commonly observed in current commercial vaccines is cause for concern, since there is no cross-immunity between serovars.

The most commonly serovars in canine leptospirosis have been Icterohaemorrhagiae and Canicola, but others serovars have emerged as significant cause of the disease. An example is the serovars Grippotyphosa and Pomona, whose prevalence in dogs has increased and which are important infectious causes of acute renal failure (ETTINGER; FELDMAN, 2004). The serovar Pomona, which was the most prevalent in this study, has been reported by other authors at only 1.6% and 0.74% (PETRUCCI et al., 2002). However, another research (TESSEROLLI et al., 2008) found a prevalence of 32.27% (193/598) with serovars of higher prevalence reported as Copenhageni (71.50%) and Canicola (6.74%), accompanied by Icterohaemorrhagiae (2.08%).

The complains and clinical signs evaluated in decreasing order of frequency were apathy (100.00%), anorexia/dysorexia (100.00%), adypsia (83.33%), ocular secretion (66.66%), reactive lymph nodes (66.66%), diarrhea (58.33%), vomiting, anemia and fever (41.66%). These signs were similar to those found in previous studies (LAPPIN, 2010) which determined that the clinical signs commonly observed in animals infected with leptospirae were lethargy, apathy, anorexia, vomiting, fever, diarrhea and others.

From the 42 dogs with leptospirosis evaluated by Geisen et al. (2007) 81.00% had presented lethargy, 76.00% anorexia, 57.00% vomiting, 52.00% weakness, 40.00% diarrhea and 17.00% had weight loss. At clinical examination, 45.00% had presented jaundice and 31.00% dehydration, abdominal pains and brownish urine.

The determination of clinical aspects of dogs infected with *E. canis* described Nakaghi et al. (2008) were apathy (60.70%), anorexia (56.70%), pale mucosae (43.30%), fever (43.30%), lymphadenomegaly, hepatomegaly and/or splenomegaly (43.30%), and uveitis (40.00%), followed by petechial hemorrhages or suffusions (33.30%), as the main findings in 30 dogs clinically diagnosed with ehrlichiosis.

During the acute phase of canine monocytic ehrlichiosis, Rungsipipat et al. (2009) noted fever, depression, anorexia, lymphadenopathy, diffuse bleeding, epistaxis and conjunctivitis, clinical signs which were also observed in this study.

The immune response that triggers the host to injury before the agent generates an increase in the production of interleukin-1 and antigen expression in immune cells, mainly in B lymphocytes. There is also a production of exogenous pyrogens rickettsia resulting in hyperthermia and break the balance of systems.

Shipov et al. (2008) established clinical signs of prognosis in canine ehrlichiosis and as observed in this study were pale mucous membranes, weakness and spontaneous bleeding. These signs were related mainly to the group of dogs that survived and had a worse prognosis, constituting a risk factor for mortality in ehrlichiosis in dogs. De Castro et al. (2004) described yet ascitis and splenomegaly.

The clinical signs frequently associated with canine leptospirosis depend on several factors such as the virulence of the serovar and the host's immunological status and age. The mildest forms evolve to fever, anorexia, vomiting, dehydration and apathy and the chronic form may be unapparent, culminating in chronic renal insufficiency

(SANTIM et al., 2006). The clinical changes in the chronic phase might occur because of the reactions against the agent, like as the marrow hypoplasia/aplasia. These abnormalities may be explained due to marrow suppression that occurs with depletion of cell lines (LAPPIN, 2010). Geisen et al. (2007) had determined that the clinical signals commonly associated with the infection by *Leptospira interrogans* in the dogs had been anorexia, vomiting, lethargy and weakness.

According to the hemogram (Table 1), the mean values of leukocytes, segmented neutrophils, lymphocytes and monocytes found both in dogs positive for ehrlichiosis and leptospirosis and in those positive only for ehrlichiosis were within the normal parameters. The means obtained from the erythrocyte count, measurement of the concentration of hemoglobin and the hematocrit values were lower than the normal values (FELDMAN et al., 2000; MEINKOTH; CLINKENBEARD, 2000) characterized by anemia normoregenerative normocytic and normochromic.

Thrombocytopenia, nonregenerative anemia, eosinopenia, and nuclear deviation of neutrophils to the left are frequent hematological alterations in canine ehrlichiosis (MENDONÇA et al., 2005), which were also observed in this study. In a clinical study involving 30 dogs with ehrlichiosis, 28 were confirmed through laboratory exams, the most frequent pathological and clinical findings being anemia, leukopenia and thrombocytopenia (SHIPOV et al., 2008; TESSEROLLI et al., 2008).

The results of this research agree with De Castro et al. (2004) and Rungsipipat et al. (2009) who described normoregenerative normocytic anemia, thrombocytopenia and leukopenia in blood counts in dogs with monocytic ehrlichiosis. The thrombocytopenia can be explained by the immune-mediated destruction, sequestration or by decreased production, vasculitis and platelet function abnormalities (LAPPIN, 2010).

The hematological alterations commonly observed in leptospirosis are intense leukocytosis, neutrophilia and varied degrees of anemia. Leukopenia can be established in the initial phase of the disease during leptospiremia and evolve into leukocytosis with left shift as the disease progresses. Severely affected dogs may present thrombocytopenia (GREENE et al., 2006).

Leukopenia is common in canine ehrlichiosis, but in the acute phase of the disease it may occur leucopenia, followed by leukocytosis with neutrophilia and monocytosis (LAPPIN, 2010). In this phase, dogs with ehrlichiosis may present

hematological results similar to those of dogs with leptospirosis, since both may present leukocytosis thrombocytopenia and anemia. However, the occurrence of these alterations depends on the host's immunological status.

A clinical improvement can be achieved in cases of leptospirosis that were not correctly diagnosed, since the drug of choice for the treatment of ehrlichiosis is doxycycline, which is also recommended for the treatment of leptospirosis, although it does not eliminate the renal carrier status, but decrease the excretion of leptospores in urine. Therefore, doxycycline can treat the two diseases concomitantly and lead to the remission of the symptoms (ETTINGER, FELDMAN, 2004). Clinicians should therefore be aware, since *Leptospira interrogans* may remain in the organism of the infected animal for a long time, disseminating the agent in the environment and exposing other animals, including humans, to the disease.

Albeit unspecific, the complaints and clinical signs of apathy, anorexia/dysorexia, adipsia, ocular secretion, lymphadenomegaly,

diarrhea, vomiting and hyperthermia are frequently found in canine ehrlichiosis and are present in dogs with leptospirosis and ehrlichiosis, as well as the hematological alterations of anemia and thrombocytopenia.

This study detected the occurrence of anti-*Leptospira* agglutinins in dogs infected naturally by *Ehrlichia* spp. It is suggested that, when dogs exhibit clinical and hematological aspects of ehrlichiosis, a differential diagnosis should be done for leptospirosis, since they may occur concomitantly, aggravating the possibility of zoonosis.

ACKNOWLEDGMENTS

The authors are indebted to the Veterinary Teaching Hospital of UFU, to CAPES and FAPEMIG, and to the technicians of the Laboratories of Contagious Infectious Diseases and Clinical Pathology of UFU, who contributed to this research.

RESUMO: Erliquiose e leptospirose são doenças frequentes em países tropicais, embora nem sempre seja feito o diagnóstico diferencial entre estas. Objetivou-se avaliar os sinais clínicos e as alterações hematológicas em cães reagentes para leptospirose, dentre aqueles que apresentaram mórula de *Ehrlichia* spp. e reconhecer a frequência dos sorovares de *Leptospira*, por meio do teste de aglutinação microscópica. Foram utilizadas amostras sanguíneas de 50 cães que apresentavam mórulas de *Ehrlichia* spp. em extensões de sangue coletadas dos capilares marginais da orelha. Os sinais clínicos frequentemente observados foram apatia (100,00%), anorexia/disorexia (100,00%), adipsia (83,33%), secreção ocular (66,66%), linfonodos reativos (66,66%), diarreia (58,33%), vômito, anemia e febre (41,66%). Embora inespecíficos, anemia e trombocitopenia são achados hematológicos frequentes na erliquiose canina e presente em ambas as doenças. Dos 50 cães com erliquiose, 12 (24,00%) apresentaram-se reagentes para leptospirose, sendo os sorovares mais frequentes: Pomona (33,33%) seguido pelo Canicola (27,77%) e Icterohaemorrhagiae (22,22%). Os resultados sugerem a necessidade de se estabelecer um diagnóstico diferencial entre estas doenças que podem ocorrer concomitantemente.

PALAVRAS-CHAVE: *Canis familiaris*. Erliquiose. Hematologia. Leptospirose.

REFERENCES

- ADLER, B.; DE LA PEÑA MOCTEZUMA, A. *Leptospira* and leptospirosis. **Veterinary Microbiology**, Amsterdam, v. 140, n. 3/4, p. 287-296, 2010.
- ALVES, C. J.; ANDRADE, J. S. L.; VASCONCELLOS, S. A.; MORAIS, Z. M.; AZEVEDO, S. S.; SANTOS, F. A. Avaliação dos níveis de aglutininas anti-leptospira em cães no município de Patos-PB, Brasil. **Revista Brasileira de Ciências Veterinárias**, Niterói, v. 7, n. 1, p. 17-21, 2000.
- ANDEREG, P. I.; PASSOS, L. M. F. Erliquiose canina: revisão. **Clínica Veterinária**, São Paulo, v. 4, n. 18, p. 31-38, 1999.
- ÁVILA, M. O.; FURTADO, L. R. I.; TEIXEIRA, M. M.; ROSADO, R. L. I.; MARTINS, L. F. S.; BROD, C. S. Aglutininas anti-*Leptospira* em cães na área de influência do Centro de Controle de Zoonoses, Pelotas, RS, Brasil, no ano de 1995. **Ciência Rural**, Santa Maria, v. 28, n. 1, p. 107-110, 1998.

AYRES, M.; AYRES, J. R.; AYRES, D. L.; SANTOS, A. A. S. **Bioestati 6.0: Aplicações estatísticas nas áreas das ciências-biomédicas**. 6 ed. Belém: Sociedade Civil Mamirauá, MCT - CNPq. 2007. 324p.

BRASIL. **Ministério da Saúde. Fundação Nacional de Saúde**. Centro Nacional de Epidemiologia. Coordenação de Controle de Zoonoses e Animais Peçonhentos. Manual de leptospiroses. 2 ed. Brasília:Fundação Nacional de Saúde, p. 8, 1995.

BRASIL. **Guia de vigilância epidemiológica**. Brasília: Fundação Nacional de Saúde. 2002. 842p.

COHN, L. A. Ehrlichiosis and related infections. **The Veterinary Clinical North American: Small Animal Practice**, Philadelphia, v. 33, n. 4, p. 863-884, 2003.

COSTA, J. O.; BATISTA JR, J. A.; SILVA, M.; GUIMARÃES, M. P. *Ehrlichia canis* infection in dog in Belo Horizonte, Brazil. **Arquivo da Escola Veterinária**, Belo Horizonte, v. 25, n. 2, p. 199-200, 1973.

DAGNONE, A. S.; MORAIS, H. S. A.; VIDOTTO, O. Ehrlichiosis nos animais e no homem. **Semina: Ciências Agrárias**, Londrina, v. 22, n. 2, p. 191-201, 2001.

DE CASTRO, M. B.; MACHADO, R. Z.; AQUINO, L. P. C. T.; ALESSI, A. C.; COSTA, M. T. Experimental acute canine monocytic ehrlichiosis: clinicopathological and immunopathological findings. **Veterinary Parasitology**, Amsterdam, v. 119, n. 1, p. 73-86, 2004.

DUMLER, J. S.; BARBET, A. F.; BEKKER, C. P. J.; DASCH, G. A.; PALMER, G. H.; RAY, S. C.; RIKIHISA, Y.; RURANGIRWA, F.R. Reorganization of genera in the families Rickettsiaceae and Anaplasmataceae in the order Rickettsiales: unification of some species of *Ehrlichia* with *Anaplasma*, *Cowdria* with *Ehrlichia* and *Ehrlichia* with *Neorickettsia*, descriptions of six new species combinations and designation of *Ehrlichia equi* and "HE agent" as subjective synonyms of *Ehrlichia phagocytophila*. **International Journal of Systematic and Evolutionary Microbiology**, England, v. 51, n. 6, p. 2145-2165, 2001.

ETTINGER, S. J.; FELDMAN, E. C. **Tratado de medicina interna veterinária: doenças do cão e do gato**. 5ed. Rio de Janeiro: Guanabara Koogan, 2004, 2156p.

FELDMAN, B. F.; ZINKL, J. G.; JAIN, N. C. **Shalm's veterinary hematology**. 5th ed. Lippincott: Williams & Wilkins, 2000.1344p.

FURTADO, L. R. I.; AVILA, M. O.; FEHLBERG, M. F. B.; TEIXEIRA, M. M.; ROSADO, R. L. I.; MARTINS, L. F. S.; BROD, C. S. Prevalência e avaliação de fatores de risco à leptospirose canina, no município de Pelotas-RS. **Arquivo do Instituto Biológico**, São Paulo, v. 64, n. 1, p. 57-61, 1997.

GEISEN, V.; STENGEL, C.; BREM, S.; MULLER, W.; GREENE, C.; HARTMANN, K. Canine leptospirosis infections—clinical signs and outcome with different suspected *Leptospira* serogroups (42 cases). **Journal of Small Animal Practice**, Oxford, v. 48, n. 6, p. 324-328, 2007.

GREENE, C. E.; SYKES, J. E.; BROWN, C. A.; HARTMANN, K. Leptospirosis. In: GREENE, C. E. (Ed.) **Infectious diseases the dog and cat**. 3th ed. St. Louis: Saunders Elsevier, 2006. p. 402-417.

LABRUNA, M. B.; PEREIRA, M. C. Carrapatos em cães no Brasil. **Clínica Veterinária**, São Paulo, v. 6, n. 30, p. 24-32, 2001.

LAPPIN, M. Doenças riquetsianas polissistêmicas. In: NELSON, R. W.; COUTO, C. G. **Medicina interna de pequenos animais**. 4ed., Rio de Janeiro: Elsevier, 2010. p. 1322-1335.

MAGALHÃES, D. F.; SILVA, J. A.; MOREIRA, E. C. Prevalência de aglutininas anti-*Leptospira interrogans* em cães de Belo Horizonte, Minas Gerais, 2001 a 2002. **Arquivo Brasileiro de Medicina Veterinária e Zootecnia**, Belo Horizonte, v. 58, n. 2, p. 167-174, 2006.

MEINKOTH, J. H.; CLINKENBEARD, K. D. Normal hematology of the dog. In: FELDMAN, B. F.; ZINKL, J. G.; JAIN, N. C. **Schalm's veterinary hematology**, Philadelphia: Lippincott Williams & Wilkins, 2000. p. 1055-1063.

MENDONÇA, C. S.; MUNDIM, A. V.; COSTA, A. S.; MORO, T. V. Erliquiose canina: alterações hematológicas em cães domésticos naturalmente infectados. **Bioscience Journal**, Uberlândia, v. 21, n. 1, p. 167-174. 2005.

MOREIRA, S. M.; MACHADO, R.; PASSOS, L. F. Detection of *Ehrlichia canis* in bone marrow aspirates of experimentally infected dogs. **Ciência Rural**, Santa Maria, v. 35, n. 4, p. 958-960, 2005.

NAKAGHI, A. C. H.; MACHADO, R. Z.; COSTA, M. T.; ANDRÉ, M. R.; BALDANI, C. D. Canine ehrlichioses: clinical, hematological, serological and molecular aspects. **Ciência Rural**, Santa Maria, v. 38, n. 3, p. 766-770, 2008.

PETRUCCI, C. G. O.; FISCHER, C. D. B.; SIMÕES, P. N.; MOREIRA, K. A. Leptospirose canina: perfil sorológico de cães atendidos na rotina clínica do hospital veterinário na Universidade Luterana do Brasil no período de setembro de 1999 a junho de 2002. In: XXIX Congresso Brasileiro de Medicina Veterinária, CONBRAVET. **Anais...** Gramado, p. 94, 2002.

SANTIM, K.; BLACENCE, A.; NADVORNY, A.; WOLFFNBUTTEL, S.; CARDOSO, M. R. I.; SCHIMIDT, V. Pesquisa de aglutininas anti-leptospira em cães com suspeita clínica de leptospirose. **Clínica Veterinária**, São Paulo, v. 6, n. 60, p. 48-52, 2006.

RUNGSIPAT, A.; ODA, M.; KUMPOOSIRI, N.; WANGNAITAHAM, S.; POOSOONTHONTHAM, R.; KOMKAEW, W.; SUKSAWAT, F.; RYOJI, Y. Clinicopathological study of experimentally induced canine monocytic ehrlichiosis. **Comparative Clinical Pathology**, London, v. 18, n. 1, p. 13-22, 2009.

SHIPOV, A.; KLEMENT, E.; REUVENI-TAGER, L.; WANER, T.; HARRUS, S. Prognostic indicators for canine monocytic ehrlichiosis. **Veterinary Parasitology**, Amsterdam, v. 153, n. 1-2, p. 131-138, 2008.

SOUZA, L. A.; VIANA, R. C. A.; MICHALICK, M. S. M.; REIS, J. K. P.; LAGE, A. P. Prevalência da infecção por *Brucella canis* em Belo Horizonte – MG. **Revista Brasileira de Medicina Veterinária**, Niterói, v. 24, n. 3, p. 127-131, 2002.

STILES, J. Canine rickettsial infections. **The Veterinary Clinics of North America: Small Animal Practice**, Philadelphia, v. 30, n. 4, p. 1135-1149, 2000.

TESSEROLLI, G. L.; ALBERTI, J. V. A.; BERGAMASHI, C.; FAYZANO, L.; AGOTTANI, J. V. B. Principais sorovares de leptospirose canina em Curitiba, Paraná. **Pubvet**, Londrina, v. 2, n. 21, artigo 78, 2008.

THRUSFIELD, M. **Epidemiologia veterinária**. 2.ed. São Paulo: Roca, 2004. 556p.

WORLD HEALTH ORGANIZATION (WHO). **Human Leptospirosis: Guidance for Diagnosis, Surveillance and Control**. Geneva: World Health Organization/International Leptospirosis Society. 2003. 109p.