







ANALYSIS OF CLINICAL AND HEMATOLOGICAL CHARACTERISTICS AND SEARCH FOR HEMOPARASITES IN OWLS (STRIGIFORMES: STRIGIDAE) SEIZED OR RESCUED FROM THE ATLANTIC FOREST BIOME OF THE RIO DE JANEIRO (SOUTHEASTERN BRAZIL)

Sabrina Toledo DE ARAUJO¹ , Sabrina Destri Emmerick CAMPOS¹ , Andrea Yuri TAKITANI² , Jeferson Rocha PIRES³ , Aline Moreira DE SOUZA¹ , Nádia Regina Pereira ALMOSNY¹ 

¹ Postgraduate Program in Veterinary Medicine, Universidade Federal Fluminense, Niterói, Rio de Janeiro, Brazil.

² Instituto Estadual do Ambiente, Rio de Janeiro, Rio de Janeiro, Brazil.

³ Wild Animal Recovery Center, Universidade Estácio de Sá, Rio de Janeiro, Rio de Janeiro, Brazil.

Corresponding author:

Sabrina Toledo de Araujo
sabrinet.silvestres@yahoo.com.br

How to cite: DE ARAÚJO, S.T., et al. Analysis of clinical and hematological characteristics and search for hemoparasites in owls (Strigiformes: Strigidae) seized or rescued from the Atlantic Forest biome of the Rio de Janeiro (southeastern Brazil). *Bioscience Journal*. 2023, 39, e39086. <https://doi.org/10.14393/BJ-v39n0a2023-65777>

Abstract

Hemoparasitism is known to vary according to the presence of vectors and hosts, and hematological examination can be a useful tool for early diagnosis in avian medicine, contributing to monitoring and conservation of bird populations. In this context, we aimed to analyze the clinical and hematological aspects of free-ranging owls seized or rescued from the Atlantic Forest biome of Rio de Janeiro, Brazil. The animals, with or without clinical signs of diseases, were studied regardless of their age, sex, and physical status. Blood samples were collected and complete blood counts were carried out. Five different species were obtained in this study. These species were *Megascops choliba* (50%), *Asio clamator* (18.75%), *Athene cunicularia* (18.75%), *Pulsatrix koenigswaldiana* (6.25%), and *Strix huhula* (6.25%). Orphaned birds and traumatic injuries were the causes of admission to the wildlife rehabilitation facility. The search for hemoparasites revealed infection by protozoa of the genera *Haemoproteus*, *Plasmodium*, and *Trypanosoma*. We concluded that hematological findings in seized or rescued owls predominantly suggested the presence of stress or inflammation resulting from post-traumatic situations. The causes of admission were mostly due to human interference, which demonstrates to have a negative impact on the health aspect of owl populations in urban centers, such as Rio de Janeiro. Blood protozoa are circulating among the different populations of owls and although infection by *Haemoproteus* spp. and *Trypanosoma* spp. seems to trigger a low pathogenic potential, *Plasmodium* infection may indicate unfavorable prognosis, endangering wild species.

Keywords: Birds of Prey. Haemosporida. Hematology. Trypanosomatidae. Wild Animals.

1. Introduction

Birds are a heterogeneous group with different anatomical and physiological characteristics. The term “bird of prey” is used to designate carnivorous birds that have highly efficient predatory adaptations and are essential for population regulation because they are at the top of the food chain (Ward et al. 2002; Andery et al. 2013). Brazil is among the countries with the richest avifauna along with other South American countries (Pacheco et al. 2021). Unfortunately, raptor populations are currently threatened by

anthropogenic activities, including hunting, trafficking, persecution, and conflict with humans (Soares et al. 2008).

In bird medicine, the time until the diagnosis is confirmed is a crucial factor, as birds may be able to mask the signs of illness, which in addition to the lack of knowledge of the peculiarities of the species on the part of the bird keeper, ensures that the disease is at an advanced stage when noticed (Malley 1996). Thus, hematology is an essential, minimally invasive component in veterinary practice, assisting in the early diagnosis (Mitchell and Johns 2008).

In the context of hematological analysis, blood parasites, including those of the order Haemosporida, are present in raptor species (Leppert et al. 2008; Santos et al. 2008). Hemosporid infections are well tolerated by many species of birds; however, there is evidence that parasitism can negatively affect bird populations (Marzal et al. 2005; Tomé et al. 2005).

As the occurrence of hemoparasites varies according to the geographical distribution of their hosts and vectors, studies on the hematology of raptors can significantly contribute to the monitoring and conservation programs of these species regionally. Thus, this study aimed to analyze the clinical and blood aspects of owls seized or rescued from the Atlantic Forest biome of Rio de Janeiro.

2. Material and Methods

This study was approved by the Fluminense Federal University Ethics Committee on Animal Research (reference no. 394).

In this study, owls (Strigiformes: Strigidae) seized or rescued with or without clinical signs of diseases and admitted to the wildlife rehabilitation facility of the Universidade Estácio de Sá, Rio de Janeiro municipality, Brazil (22° 58' 46" S, 43° 27' 24" W) were studied between March 2012 and October 2013. All the birds were included in this study, regardless of their age, sex, and physical status.

Using physical restraint, blood samples were collected from the jugular or brachial veins, and whole blood was placed in ethylenediaminetetraacetic acid (EDTA) tubes, the collections did not exceed 72 hours after admission of the birds. At the time of sampling, the animals were examined using routine noninvasive procedures and relevant findings were registered where the oral cavity, pectoral musculature, eyes, hydration status, coelomic cavity were evaluated Cardiac and pulmonary auscultation was performed.

Using the blood in the EDTA tubes, microhematocrit tubes were filled and centrifuged to determine the packed cell volume (PCV). Red blood cell (RBC), thrombocyte, and white blood cell (WBC) counts were carried out in Neubauer counting chambers using Natt-Herrick's solution at a 1:100 dilution. Hemoglobin concentration was measured by spectrophotometry using the cyanometahemoglobin method after centrifugation to remove free erythrocyte nuclei. The mean corpuscular volume (MCV) and mean corpuscular hemoglobin concentration (MCHC) were calculated following the standard methods used for mammals.

Blood films were obtained immediately after blood collection and stored in boxes, fixed in methanol, and stained with Giemsa (Merck®, Rio de Janeiro, RJ, Brazil). Differential WBC counts were performed based on the count of 100 WBCs under oil immersion (1000× magnification). To verify infection by hemoparasites, four stained smears of each animal were scanned for 30 min under oil immersion, constantly changing fields, without worrying about the number of fields to be observed. Being more sensitive, molecular-based methods have been used in the detection of hemoparasites. However, the scanning protocol is considered sufficient to detect even low-intensity infections being the hemoparasites of the present study identified from the morphology, by microscopic analysis. (Fedynich et al. 1993; Tomé et al. 2005; Santos et al. 2008)

The hematological results for *Megascops choliba*, *Asio clamator*, and *Pulsatrix koeniswaldiana* were compared to the values obtained by Goulart et al. (2020). The reference values for *Athene cunicularia* were obtained in the category of both sexes combined and all ages combined from the International Species Information System (ISIS) (www.isis.org). The reference values for *Strix huhula* were not found. The results were then compared with those of another bird species, *Strix varia*, obtained from the ISIS database.

3. Results

During this study, 16 owls of five different species were evaluated. The most frequent owl found in this study was the tropical screech owl, *Megascops choliba*, which accounted for 50% (8/16) of the animals. All of them were orphaned, had juvenile plumage, and were clinically healthy. Another species obtained was the striped owl, *Asio clamator*, which represented 18.75% (3/16) of the birds. Of these, two were clinically healthy (one adult and one juvenile) while the other had tendon laceration due to an accident caused by a kite line. In addition, three (18.75%) burrowing owls (*Athene cunicularia*) were evaluated: one without clinical signs and two that were victims of trauma to the wing caused by kite lines and presented with tendon lacerations. The only tawny-browed owl, *Pulsatrix koeniswaldiana*, which was part of our study (6.25%), had a metacarpal fracture. One black-banded owl, *Strix huhula* (6.25%), rescued with neurological manifestations (incoordination) after a collision with a window was also assessed.

The complete blood count (CBC) values obtained in this study and the reference ranges for each bird species are shown in Table 1. After the search for hemoparasites, it was possible to identify infection by protozoa of the genera *Haemoproteus* (in one *A. cunicularia* and two *A. clamator*), *Plasmodium*, and *Trypanosoma* (co-infection in the *S. huhula*) (Table 2).

The overall frequency of infection was 25.00% (4/16); 18.75% (3/16) for *Haemoproteus* spp. and 6.25% (1/16) for the genera *Plasmodium* and *Trypanosoma*.

All *M. choliba* owls had normal PCV, RBC, MCV, and thrombocytes values. However, increased hemoglobin and MCHC were observed in 25.0% of the sampled animals (2/8). The leukogram values were normal in all animals, except for monocytes counts.

Regarding the animals of the species *A. clamator*, which were clinically healthy at the time of sampling, most of their hematological parameters were within normal values, except for the presence of leukocytosis and increase in heterophils in one of these birds, and monocytosis in the other one. The striped owl (*A. clamator*), which was referred to the rehabilitation center with traumatic injury due to a kite line accident also presented with leukocytosis and heterophilia. In the evaluation of the blood smear, parasitic intra-erythrocytic forms morphologically compatible with gametocytes of *Haemoproteus* spp. were present in two animals, 659 (apparently healthy) and 684 (traumatized).

The CBC of an adult owl, *A. cunicularia*, sent to the rehabilitation center without clinical abnormalities (613), revealed basopenia, lymphopenia, and the presence of band heterophils. With regard to this species, *A. cunicularia*, an adult individual (643), which was rescued after the laceration of a tendon by an accident with a kite line, presented a reduction in the PCV and RBC count, an elevation above the reference limits in the MCHC, WBC, heterophil, and monocyte counts, eosinopenia, and basopenia. In addition to heterophilia, this animal had toxic heterophils. A blood smear examination of the same owl (*A. cunicularia* 643) revealed parasitic intra-erythrocytic forms compatible with gametocytes of *Haemoproteus* spp. (Figures 1A and 1B). Another case of traumatic injury caused by a kite line was also observed in *A. cunicularia*. This bird presented with discrete leukocytosis with heterophilia; however, the basophils and lymphocytes counts were below the normal range.

The CBC of the tawny-browed owl, *P. koeniswaldiana*, revealed an increase in the MCV and a decrease in the total counts of erythrocytes, leukopenia, heteropenia, eosinopenia, and basopenia, while the counts of monocytes were increased.

Regarding the *S. huhula* species, hematological results revealed a decrease in the PCV and an increase in the MCV and MCHC. Leukopenia with lymphopenia and basopenia have also been observed. Hemoparasite research revealed the presence of intra-erythrocytic forms characteristic of the *Plasmodium* genus (Figure 1C and 1D) in addition to flagellate forms showing a single nucleus, kinetoplast, and undulating membrane compatible with *Trypanosoma* spp. (Figure 1E and 1F).

4. Discussion

All rescued cases of *M. choliba* were related to juvenile and orphaned birds. According to a study by Komnenou et al. (2005), in free-living raptors, orphaned birds are usually found during the breeding season, mainly because of inappropriate human intervention. In view of this report, it is possible that the

same was observed in our study especially because according to Motta-Junior (2006), *M. choliba* is very generalist in the use of the habitat, with a tendency to inhabit peri-urban areas where they can easily interact with humans.

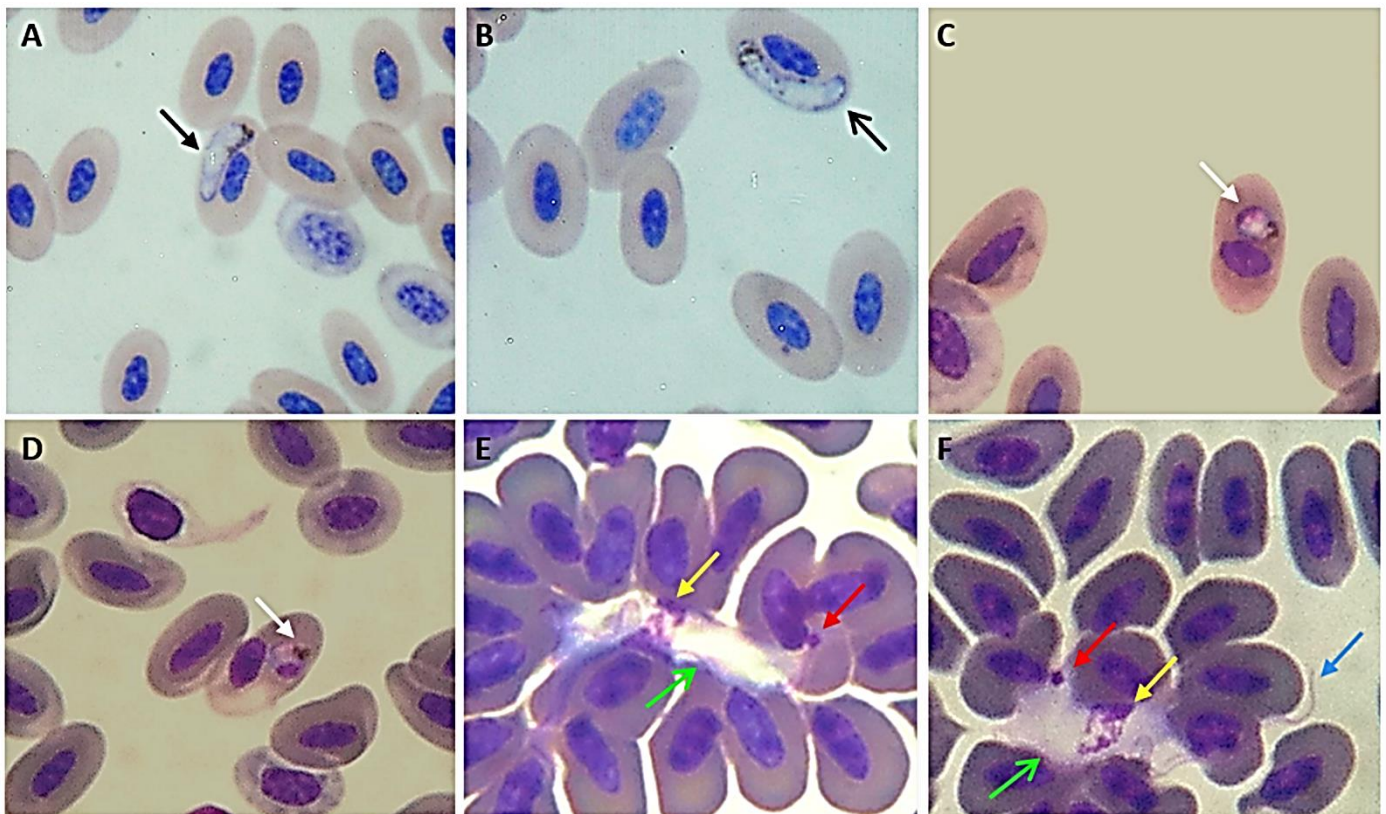


Figure 1. Photomicrographs of blood parasites in Giemsa-stained blood smears (oil immersion at 1000× magnification) from owls (Strigiformes: Strigidae) seized or rescued from the Atlantic Forest biome of the Rio de Janeiro and admitted in a wildlife rehabilitation center. Personal archive. A and B: Presence of *Haemoproteus* spp. gametocyte (black arrows) within erythrocytes of *Athene cunicularia*. C and D: Presence of intra-erythrocytic inclusions compatible with the trophozoites of *Plasmodium* spp. (white arrows) within erythrocytes of *Strix huhula*. E and F: Presence of the protozoan (*Trypanosoma* spp.) showing a single nucleus (yellow arrows), kinetoplast (red arrows), undulating membrane (green arrows), and the flagellum (blue arrow) in a specimen of *Strix huhula*.

In the present study, the hematological results of *M. choliba* were expected, since only birds without any evident signs of disease were sampled. Increased MCHC values in birds of this species were considered of little concern, because it was not possible to rule out discrete pre-analytical hemolysis. Previously, de Jonge et al. (2018), comparing peripheral blood samples with different degrees of hemolysis showed that a mild degree of hemolysis can lead to a slight increase in MCHC. According to the authors, *in vitro* (artificial) hemolysis falsely increases the MCHC and usually involves factors such as small and fragile veins that are easily traumatized. This fact may have occurred in the present study due to the small size of the animals. After using mean and standard deviation values for *Megascops* spp. (Goulart et al. 2020), we observed monocytosis in 87.5% of the tropical screech owls in the present study. However, according to the authors, the monocyte values of *Megascops* spp. and *A. clamator* did not show normal distribution, and were, therefore, expressed by descriptive statistics, rather than a reference interval. Compared to the results obtained in eastern screech owls (*Megascops asio*) we no longer detected monocytosis (Ammerbach et al. 2015).

In the present study, injuries to the wing caused by kite lines affected 18.75% of the birds (one *A. clamator* and two *A. cunicularia*). The *A. clamator* owl usually inhabits densely foliated bushes and presents predominantly crepuscular and nocturnal activity, which tends to make the occurrence of human interventions difficult (Motta-Junior 2006). Even so, injuries caused by kite lines have been previously recorded for this species in Brazil (Andery et al. 2013).

Table 1. Hematological results for owls (Strigiformes: Strigidae) from a wildlife rehabilitation facility at the Rio de Janeiro municipality.

Animal	History	PCV %	RBC ×10 ⁶ /μL	Hb g/dL	MCV fL	MCHC %	T ×10 ³ /μL	WBC ×10 ³ /μL	Ba ×10 ³ /μL	Eo ×10 ³ /μL	Het ×10 ³ /μL	Ly ×10 ³ /μL	Mo ×10 ³ /μL
<i>Tropical screech owls (Megascops choliba)</i>													
1 -young	orphaned	40	1.90	12.4	210.52	31.0	25	6	0	0.06	3.12	0.9	1.92
2 -young	orphaned	38	1.18	11.5	322.03	30.3	20	5	0	0.1	2.75	1.5	0.65
3 -young	orphaned	40	1.28	14.9	312.50	37.2	30	8	0	0.48	4.8	1.12	1.6
4 -young	orphaned	37	1.62	11.6	228.39	31.3	22	7	0	0.35	3.78	1.89	0.98
5 -young	orphaned	33	1.92	11.2	171.87	33.9	32	12	0	0.24	6	3.36	2.4
6 -young	orphaned	38	1.68	10.0	226.19	26.3	20	9	0	0.54	4.5	2.52	1.44
7 -young	orphaned	35	1.18	12.6	296.61	36.0	18	10	0	0.2	6	2.5	1.3
8 -young	orphaned	39	1.44	11.8	270.83	30.3	18	14	0	0.28	7.7	4.2	1.82
Reference	-	29.7- 44.6	0.8- 2.3	6.4-12.4	131.6- 374.4	12.1-34	10.3-43.6	0.7-23.1	0.0-0.7	0.0-2.2	1.1-10.3	0.0-11.5	-
<i>Striped owls (Asio clamator)</i>													
623-young	Healthy	32	2.0	9.1	160.0	28.4	54.25	28	0	1.12	22.4	4.2	0.28
659-adult	Healthy	30	1.6	10.0	187.5	33.3	35.5	18.4	0	0	15.64	2.02	0.74
684-adult	Trauma	40	2.1	9.0	190.48	22.5	47	30	0	0.6	19.2	9.6	0.6
Reference	-	30.2- 50.1	1.0-2.5	6.7-15.3	123.8- 355.2	17.1- 38.6	10.8-56.6	1.2-23.6	0.0-1.0	0.0-1.9	0.6-16.6	0.6-10.2	-
<i>Burrowing owls (Athene cunicularia)</i>													
613-adult	Healthy	49	2.5	10.5	196.0	21.4	46.75	11.7	0	0.11	11.0*	0.47	0.12
643-adult	Trauma	28	1.3	11.3	215.38	40.4	35.25	15.1	0	0	8.46	5.13	1.51
684b-adult	Trauma	41	1.8	11.8	227.77	28.8	20	13.9	0	0.14	12.37	1.25	0.14
Reference ¹	-	45.1± 5.7	2.23± 0.47	15.9± 8.5	199.9± 43.6	30.1± 9.0	-	8.869± 4.558	0.495± 0.448	0.926± 0.908	3.777± 3.090	3.234± 1.972	0.476± 0.401
<i>Tawny-browed owl (Pulsatrix koeniswaldiana)</i>													
Adult	Fracture	38	1.18	11.5	322.03	30.26	28	7	0	0.07	3.99	2.1	0.84
Reference ²	-	38;41	1.5;2.4	9.5;12	255;171.9	25;29.6	25.3;73.9	10.0;18.0	0.4;0.18	2.5;3.2	5.3;11.5	1.8;3.0	0
<i>Black-banded owl (Strix huhula)</i>													
Adult	Trauma	31	1.0	12.8	310.0	41.3	20	5	0	0.4	3.5	0.5	0.6
Reference ^{1,3}	-	40.3± 4.5	2.79± 1.9	11.9± 1.2	168.5± 57.1	30.3± 4.2	-	13.360± 6.504	0.991± 0.967	0.975± 0.814	6.268± 3.847	5.439± 3.271	0.66± 0.618

¹Reference range expressed as mean ± standard deviation (International Species Information System); ²Individual hematological values for captive *Pulsatrix koeniswaldiana* (n = 2) (Goulart et al. 2020);

³Reference values for *Strix varia*. PCV, packed cell volume; RBC, red blood cells; Hb, hemoglobin; MCV, mean corpuscular volume; MCHC, mean corpuscular hemoglobin concentration; T, thrombocytes; WBC, white blood cells; Ba, basophils; Eo, eosinophils; Het, heterophils; Ly, lymphocytes; Mo, monocytes. *Results including 4320 band heterophils.

Table 2. Number and percentage of owls (Strigiformes: Strigidae) examined and infected by hemoparasites in a wildlife rehabilitation facility at the Rio de Janeiro municipality.

Taxon	Birds; n (%)		Birds infected with		
	Examined	Infected	H	P	T
<i>Asio clamator</i>	3 (18.75)	2 (12.50)	2	0	0
<i>Athene cunicularia</i>	3 (18.75)	1 (6.25)	1	0	0
<i>Megascops choliba</i>	8 (50.00)	0	0	0	0
<i>Pulsatrix koeniswaldiana</i>	1 (6.25)	0	0	0	0
<i>Strix huhula</i>	1 (6.25)	1 (6.25)	0	1	1
Total	16 (100.00)	4 (25.00)	3	1	1

H: *Haemoproteus* spp.; P: *Plasmodium* spp.; T: *Trypanosoma* spp.

The results of the leukogram in the *A. clamator* specimens were not an issue of concern. McRee et al. (2018) testing effect of transportation, restraint, and common clinical procedures such as blood samples collection, demonstrated that white blood cells and heterophils counts increased over time in the tested group, featuring a stress leukogram.

Parga et al. (2001) reported on how haematological changes in raptors can occur due to numerous stressors, such as social disruption, elevated temperatures, behavioral restriction and mechanical restraint. The cells that are most affected under stress conditions are heterophils and lymphocytes, with the heterophil/lymphocyte ratio (H/L) being a precise indicator to assess stress in birds, including birds of prey.

However, we cannot rule out the fact that one animal presented trauma and parasitic inclusions that were morphologically compatible with *Haemoproteus* spp. gametocytes. It is important to remember that the bird did not show clinical signs at the time of sampling and that the low pathogenicity of infections by the genus *Haemoproteus* is commonly reported (Andery et al. 2013; Campbell 2015). Even so, the possibility that the leukogram abnormalities may be a form of response to both traumatic wing injury and hemoparasitism cannot be excluded. The elevation of monocytes counts in one of the *A. clamator* specimens was not a concern, as it was discreet or absent when compared with those of other species of the same genus (Ammersbach et al. 2015; Montolio et al. 2017).

According to Motta-Junior (2006), *A. cunicularia* generally remains in places of easy visibility. Menezes and Ludwig (2013) also highlighted that this is one of the most common owls in Brazil, which is widely adapted to the urban environment and proximity to humans and is commonly observed on walls, fences, and wires. Another peculiarity is that unlike the other species of Strigiformes, *A. cunicularia* has a very active diurnal habit (Motta-Junior 2006; Menezes and Ludwig 2013). Based on the ecological aspects described above, it is suggested that the conspicuous and day-long behavior of this species may have facilitated the accidents with kite lines observed in the present study.

Anemia, leukocytosis, heterophilia and monocytosis in *A. cunicularia* victims of trauma can be attributed to inflammation and blood loss, as traumatic injuries are among the most common causes of hemorrhagic anemia (Campbell 2015). In addition, it is known that heterophils are important first cellular responders to inflammatory conditions (Stacy et al. 2022). Infection with *Haemoproteus* spp., which was observed under microscopy, may have contributed to the abnormalities found, and probably led to an increase in the MCHC. Toxic heterophils in blood smears of this animal were also accounted for by the infectious process, as has been proposed before (Stacy et al. 2022). The presence of band heterophils, despite the absence of evident clinical signs, does not allow us to rule out the possibility of an inflammatory and/or infectious process in animal 613 since many birds can mask the signs of disease (Malley 1996; Mitchell and Johns 2008). In addition to quantitative elevation of heterophils in blood circulation, inflammatory states often have accompanying increases in immature precursor stages (Stacy et al. 2022).

The *P. koeniswaldiana* evaluated in this study presented a bone fracture. Although this was the only case of bone fracture that we detected, other studies have previously reported high fracture rates in birds of prey, both in the thoracic limbs and in the pelvic limbs and other bone structures (Naldo and Samour 2004; Andery et al. 2013). Reference hematological values for *P. koeniswaldiana* are difficult to determine. In a large study on the hematology of birds of prey in Brazil, Goulart et al. (2020) found only two specimens of this species. Erythrogram and leukogram variations were discreet and possibly associated with stress or

the inflammatory process resulting from the injury. Campbell (2015) suggested that eosinopenia can be due to nothing more than stress, whereas monocytosis may have been associated with inflammation. It is worth mentioning that the results found in the present study did not differ significantly from the findings of a case of fracture in the wing of a Lesser Flamingo (*Phoeniconaias minor*) in Kenya (Nyariki et al. 2019).

The *S. huhula* specimen was rescued with neurological symptoms after a collision with a window. A retrospective study on Strigiformes in the United States and Canada showed that vehicle and window collisions are important causes of mortality in most owl species (Hager 2009). Despite its wide distribution in South America, the black-banded owl is a lesser-known and studied species of the Strigidae family, with scarce occurrence and records of few animals reported in Brazil. This justifies the difficulty in finding reference hematological values for *S. huhula*. Its appearance has been observed mainly in low-lying locations (with humid forests) but also in man-made habitats, plantations, and urban environments (Gonzaga and Castiglioni 2004; Lemos and Freitas 2009; Nascimento et al. 2018). The most recent records of this species in the state of Rio de Janeiro were published by Gonzaga and Castiglioni (2004) and Lemos and Freitas (2009).

The animal in question presented an erythrogram compatible with hemolytic anemia, which is sustained by a decrease in the PCV, and an increase in the MCHC. We believe that these findings were due to hemoparasite infections. Protozoa of the genus *Plasmodium* cause avian malaria, a parasitic infectious disease capable of triggering hemolytic anemia and of great epidemiological importance in birds found in tropical and humid areas (Campos et al. 2014). In contrast, parasites of the *Trypanosoma* spp., in general, are considered accidental findings in the blood smears of birds (Campbell 2015). Leukopenia, with basopenia, and lymphopenia characterized the leukogram of this animal. During a study on the hematological values of Magellanic penguins, *Spheniscus magellanicus*, with the detection of avian malarial parasites (*Plasmodium* spp.), Campos et al. (2014) also observed a reduction in the WBC, basophil, and lymphocyte counts in infected birds. According to the authors, leukopenia and basopenia due to infectious and inflammatory processes can be considered an unfavorable prognosis, indicating that the production rate is below demand. In addition, according to this study, lymphopenia in *Plasmodium* spp. infection suggests the presence of chronic stress, with lymphoid tissue atrophy and a consequent reduction in the number of circulating lymphocytes.

Regarding the frequency of hemoparasites, it was possible to observe that our results are in accordance with those of previous studies that demonstrated that blood parasites are present in several species of predators. Andery et al. (2013) observed a rate of 22.8% of *Haemoproteus* spp. infection in blood smears of Strigiformes in Brazil. The authors did not associate the clinical signs with hemoparasitism in the evaluated prey. During our study, it was also not possible to associate the presence of clinical manifestations with parasitism; however, laboratory abnormalities, such as an increase in the MCHC and monocytosis, were constant in the infected birds.

Similar to our observations, Leppert et al. (2008) found a percentage of 20% and 4% of infection by *Haemoproteus* spp. and *Trypanosoma* spp., respectively, in forest owls from the Western United States. During a study on hemoprotozoan infection (genera *Haemoproteus* and *Leucocytozoon*) in Falconiformes and Strigiformes in rehabilitation centers in Portugal, Santos et al. (2008) reported that the percentage of samples positive for at least one agent was 20.4%, a rate also similar to that found in our study. In the microscopic evaluation of blood smears, Krone et al. (2008) reported 19.8% of infections by hemosporid parasites in birds of prey in Germany, including 5.9% positivity for the genus *Plasmodium* and 4.9% for the genus *Haemoproteus*. Salakij et al. (2018) found *Haemoproteus* gametocytes in 37.8% of owl blood smears from Thailand.

Aguiar and Marçal Junior (2021) carried out a survey on hemoparasitosis in various captive birds in Brazil. The authors also used optical microscopy as the method of choice and, although molecular methods are more frequently used, we cannot ignore their higher cost as a limiting factor. Differing from our results, infection was not observed in birds of prey and only the genus *Plasmodium* was found in their study.

Although previous studies have suggested that infections by hemoparasites are well tolerated by their hosts (Andery et al. 2013; Campbell 2015), some authors believe that hemoparasitism may have a negative impact on bird populations, being considered a species selection factor (Marzal et al. 2005; Tomé et al. 2005; Campos et al. 2014). We cannot rule out the possibility that the presence of blood protozoa

has compromised the health status of parasitized birds, making them more susceptible to the accidents observed in this study (accidents with kite line and collision against a window). In addition, Campos et al. (2014) observed that avian malaria can cause neurological manifestations in infected penguins. Thus, it is difficult to determine whether the symptoms presented by *S. huhula* were due to an infection by the protozoan or the collision.

5. Conclusions

In the present study, the rescue of orphaned birds and birds with traumatic injuries (kite line accidents, collisions, and fractures) were abnormalities related to the causes of admission to the wildlife rehabilitation center, although clinically healthy birds were also observed.

We believe that habitat destruction, adaptation to the urban environment, and constant human pressure favored the conflicts that have occurred between the birds assessed and the local human population, with negative impacts on the health status of the owl populations in Rio de Janeiro. Thus, our results can contribute to epidemiological and health studies in birds of prey, since although some species of owls are quite common and have a wide geographical distribution, there are still few reports and studies on their clinical and hematological aspects.

Hematological data predominantly suggested the presence of inflammation and stress, which was in accordance with the clinical presentations of the animals. Hemoparasitic infections have also been reported. The genera *Haemoproteus* and *Trypanosoma* appeared to trigger infections with a low pathogenic potential for its hosts, but with slight and moderate variations in erythrogram and leukogram, including hemolysis, leukocytosis, heterophilia and monocytosis. In contrast, *Plasmodium* spp. seemed to be associated with an unfavorable prognosis and chronic stress, causing hemolytic anemia, leukopenia, basopenia, and lymphopenia.

Authors' Contributions: DE ARAÚJO, S.T.: conception and design, acquisition of data, analysis and interpretation of data, and drafting the article; CAMPOS, S.D.E.: acquisition of data, analysis and interpretation of data, and drafting the article; TAKITANI, A.Y.: acquisition of data and analysis and interpretation of data; PIRES, J.R.: acquisition of data and analysis and interpretation of data; DE SOUZA, A.M.: analysis and interpretation of data and critical review of important intellectual content; ALMOSNY, N.R.P.: conception and design, analysis and interpretation of data, and critical review of important intellectual content. All authors have read and approved the final version of the manuscript.

Conflicts of Interest: The authors declare no conflicts of interest.

Ethics Approval: This study was approved by the Fluminense Federal University Committee on Ethics in Animal Use (CEUA), under the reference number 394.

Acknowledgments: The authors would like to extend gratitude to Coordenação de Aperfeiçoamento de Pessoal de Nível Superior (Capes) for scholarship. We also would like to thank Editage (www.editage.com) for English language editing.

References

- AGUIAR, L.M. and MARÇAL JÚNIOR, O. Hemoparasites in captive birds at Uberlândia zoo, state of Minas Gerais, Brazil. *Bioscience Journal*. 2021, **37**, e37011. <https://doi.org/10.14393/BJ-v37n0a2021-47818>
- AMMERSBACH, M., et al. Laboratory blood analysis in Strigiformes—part I: hematologic reference intervals and agreement between manual blood cell counting techniques. *Veterinary clinical pathology*. 2015, **44**(1), 94–108. <https://doi.org/10.1111/vcp.12229>
- ANDERY, D.A., et al. Health assessment of raptors in triage in Belo Horizonte, MG, Brazil. *Brazilian Journal of Poultry Science*. 2013, **15**(3), 247–256.
- CAMPBELL, T.W., 2015. Hematologia das Aves. In: M.A. THRALL, G. WEISER, R.W. ALLISON and T.W. CAMPBELL, eds. Hematologia e Bioquímica Clínica Veterinária. 2ed. São Paulo: Roca, pp.507-593.
- CAMPOS, S.D.E., et al. Analysis of hematologic and serum chemistry values of *Spheniscus magellanicus* with molecular detection of avian malarial parasites (*Plasmodium* spp.). *Pesquisa Veterinária Brasileira*. 2014, **34**(12), 1236-1242, 1236–42. <https://doi.org/10.1590/S0100-736X2014001200016>

- DE JONGE, G., et al. Interference of in vitro hemolysis complete blood count. *Journal of clinical laboratory analysis*. 2018, **32**(5), e22396. <https://doi.org/10.1002/jcla.22396>
- FEDYNICH, A.M., PENCE, D.B. and GODFREY JR, R.D. Hemosporids (Apicomplexa, Hematozoa, Hemosporida) of anatids from the southern high plains of Texas. *Journal of the Helminthological Society of Washington*. 1993, **60**(1), 35–38.
- GONZAGA, L.P. and CASTIGLIONI, G.D.A. Registros recentes de *Strix huhula* no estado do Rio de Janeiro (Strigiformes: Strigidae). *Ararajuba*. 2004, **12**(2), 141–44.
- GOULART, M.A., et al. Hematological parameters and total plasma protein values of captive strigiformes occurring in Brazil. *Semina: Ciências Agrárias*. 2020, **41**(5 supp 1), 2129-2142.
- HAGER, S.B. Human-related threats to urban raptors. *Journal of Raptor Research*. 2009, **43**(3), 210–226. <https://doi.org/10.3356/JRR-08-63.1>
- KOMNENOU, A.T., et al. A retrospective study of presentation, treatment, and outcome of free-ranging raptors in Greece (1997–2000). *Journal of Zoo and Wildlife Medicine*. 2005, **36**(2), 222–228. <https://doi.org/10.1638/04-061.1>
- KRONE, O., et al. Haemosporidian blood parasites in European birds of prey and owls. *Journal of Parasitology*. 2008, **94**(3), 709–715. <https://doi.org/10.1645/GE-1357.1>
- LEMONS, M. and FREITAS, A.A.R. Ocorrência de coruja-preta, *Strix huhula* (Strigidae, Aves), em área urbana de Niterói, Estado de Rio de Janeiro, Brasil. *Neotropical Raptor Network*. 2009, **8**, 10–11.
- LEPPERT, L.L., et al. Survey of blood parasites in two forest owls, Northern Saw-whet Owls and Flammulated Owls, of western North America. *Journal of wildlife diseases*. 2008, **44** (2), 475–479. <https://doi.org/10.7589/0090-3558-44.2.475>
- MALLEY, D. Handling and clinical examination of psittacine birds. *In Practice*. 1996, **18**(7), 302–311. <https://doi.org/10.1136/inpract.18.7.302>
- MARZAL, A., et al. Malarial parasites decrease reproductive success: an experimental study in a passerine bird. *Oecologia*. 2005, **142**(4), 541–545.
- MCREE, A.E., et al. Effect of routine handling and transportation on blood leukocyte concentrations and plasma corticosterone in captive hispaniolan amazon parrots (*Amazona ventralis*). *Journal of Zoo and Wildlife Medicine*. 2018, **49**(2), 396-403. <https://doi.org/10.1638/2016-0100.1>
- MENEZES, L.N. and LUDWIG, P.R. Diversidade alimentar da Coruja-Buraqueira (*Athene cunicularia*) em ambiente antropomorfizado no município de Maracá/SP. *Journal of Health Sciences*. 2013, **31**(4), 347–50. http://repositorio.unip.br/wp-content/uploads/2020/12/V31_n4_2013_p347-350.pdf
- MITCHELL, E.B. and JOHNS, J. Avian hematology and related disorders. *Veterinary Clinics of North America: Exotic Animal Practice*. 2008, **11**(3), 501–522. <https://doi.org/10.1016/j.cvex.2008.03.004>
- MONTOLIO, S., et al. Hematologic reference intervals and age effect in European Strigiformes. *Veterinary clinical pathology*. 2017, **46**(3), 483–495. <https://doi.org/10.1111/vcp.12516>
- MOTTA-JUNIOR, J.C. Relações tróficas entre cinco Strigiformes simpátricas na região central do Estado de São Paulo, Brasil. *Revista Brasileira de ornitologia*. 2006, **14**(4), 359–377.
- NALDO, J.L. and SAMOUR, J.H. Radiographic findings in captive falcons in Saudi Arabia. *Journal of Avian Medicine and Surgery*. 2004, **18**(4), 242–256. Available from: <https://doi.org/10.1647/2003-027>
- NASCIMENTO, J.M., et al. Ocorrência de coruja-preta, *Strix huhula* (Strigiformes: Strigidae), na área urbana de Campo Grande, Mato Grosso do Sul: implicações à conservação. *Atualidades ornitológicas*. 2018, **202**, 1-4.
- NYARIKI, T.M., et al. Hematologic values of healthy and sick free-ranging lesser flamingos (*Phoeniconaias minor*) in Kenya. *Journal of wildlife diseases*. 2019, **55**(1), 123–128. <https://doi.org/10.7589/2016-04-079>
- PACHECO, J.F., et al. Annotated checklist of the birds of Brazil by the Brazilian Ornithological Records Committee – second edition. *Ornithology Research*. 2021, **29**(2), 94–105. <https://doi.org/10.1007/s43388-021-00058-x>
- PARGA, M.L., PENDL, H. and FORBES, N.A. The effect of transport on hematologic parameters in trained and untrained Harris's hawks (*Parabuteo unicinctus*) and peregrinefalcons (*Falco peregrinus*). *Journal of Avian Medicine and Surgery*. 2001, **15**(3), 162-169. [https://doi.org/10.1647/1082-6742\(2001\)015\[0162:TEOTOH\]2.0.CO;2](https://doi.org/10.1647/1082-6742(2001)015[0162:TEOTOH]2.0.CO;2)

SALAKIJ, C., et al. Haemoproteus in barn and collared scops owls from Thailand. *Journal of Veterinary Science*. 2018, **19**(2), 280–289. <https://doi.org/10.4142/jvs.2018.19.2.280>

SANTOS, N.G., et al. Pesquisa de hemoprotozoários em aves de rapina (ordens Falconiformes e Strigiformes) em centros de recuperação em Portugal Study of haemoprotozoa in birds of prey (orders Falconiformes and Strigiformes) in wildlife rehabilitation facilities in Portugal. *Revista Portuguesa de Ciências Veterinárias*. 2008, **103**(567-568), 195-200.

SOARES, E.S., et al. Plano de Ação Nacional para a Conservação de Aves de Rapina - série Espécies Ameaçadas. 5ª ed. Brasília: ICMBio, 2008. Available from: <https://www.icmbio.gov.br/portal/images/stories/docs-pan/pan-aves-de-rapina/1-ciclo/pan-aves-de-rapina-livro.pdf>

STACY, N.I., et al. Left shift and toxic change in heterophils and neutrophils of non-mammalian vertebrates: A comparative review, image atlas, and practical considerations. *Veterinary Clinical Pathology*. 2022, **51**(1), 18-44. <https://doi.org/10.1111/vcp.13117>

TOMÉ, R., et al. Factors affecting the prevalence of blood parasites of Little Owls *Athene noctua* in southern Portugal. *Ornis Fennica*. 2005, **82**(2).

WARD, A.B., WEIGL, P.D. and CONROY, R.M. Functional morphology of raptor hindlimbs: implications for resource partitioning. *The Auk*. 2002, **119**(4), 1052–63. <https://doi.org/10.1093/auk/119.4.1052>

Received: 23 May 2022 | **Accepted:** 10 April 2023 | **Published:** 9 June 2023



This is an Open Access article distributed under the terms of the Creative Commons Attribution License, which permits unrestricted use, distribution, and reproduction in any medium, provided the original work is properly cited.