








# THE EFFECTIVENESS OF INSULIN THERAPY IN THE FUNCTIONAL AND MORPHOLOGICAL RECOVERY OF LEYDIG CELLS IN RATS SUBMITTED TO DIABETES MELLITUS

Alluanan Adelson do Nascimento SILVA<sup>1</sup> , Jessica Santana DE OLIVEIRA<sup>1</sup> ,  
Fernanda Carolina Ribeiro DIAS<sup>1,2</sup> , Rosana Nogueira DE MORAES<sup>3</sup> , Elizabeth Neves DE MELO<sup>4</sup> ,  
Pierre Castro SOARES<sup>1</sup> , Valdemiro Amaro DA SILVA JUNIOR<sup>1</sup> 

<sup>1</sup> Department of Veterinary Medicine, Universidade Federal Rural de Pernambuco, Recife, Pernambuco, Brazil.

<sup>2</sup> Department of Structural Biology, Universidade Federal do Triângulo Mineiro, Uberaba, Minas Gerais, Brazil.

<sup>3</sup> Department of Physiology, Universidade Federal do Paraná, Curitiba, Paraná, Brazil.

<sup>4</sup> Department of Anatomy, Universidade Federal de Pernambuco, Recife, Pernambuco, Brazil.

## Corresponding author:

Alluanan Adelson do Nascimento Silva  
alluanan@gmail.com

**How to cite:** SILVA, A.A.N., et al. The effectiveness of insulin therapy in the functional and morphological recovery of leydig cells in rats submitted to diabetes mellitus. *Bioscience Journal*. 2023, **39**, e39033. <https://doi.org/10.14393/BJ-v39n0a2023-65096>

## Abstract

The effects of systemic insulin administration at different concentrations on the testicular tissue of diabetic adult rats, induced by streptozotocin, are evaluated by the morphological analysis of spermatogenic process. Twenty-four adult male rats were divided into 1) Control Group: they received citrate buffer, by intraperitoneal injection; 2) Diabetic Group: induced by intraperitoneal injection of streptozotocin (60 mg. kg<sup>-1</sup> of body weight); 3) Insulin 50%: induced diabetes treated with half of standard dosage of insulin; 4) Insulin 100%: induced diabetes treated with standard dose of insulin. After eight weeks, animals were weighted and anesthetized; testicles were removed and processed in resin. Body and testicular weight of diabetic rats decreased when compared to that of control. Parameters increased with insulin therapy. Testosterone levels were low in diabetic animals but rates recovered after insulin therapy. Nuclear diameter and volume of Leydig cells decreased in diabetic rats although they significantly increased after insulin therapy. Results showed that the administration of insulin in diabetic rats promoted a protective effect of testicular parenchyma, enhancing efficient recovery on testosterone levels and increase in daily sperm production.

**Keywords:** Diabetes Mellitus. Insulin Therapy. Leydig Cells. Seminiferous Tubule. Testis.

## 1. Introduction

Diabetes mellitus is a metabolic disease characterized by the persistence of high serum glucose levels from unfavorable changes in the production and/or action of insulin in the body (Maresch et al. 2018; Rodacki et al. 2022). It is a critical health problem that has been intensifying worldwide, with many adverse effects over time, such as retinopathy, nephropathy, cardiovascular symptoms, and sexual dysfunction (Joshi et al. 2017; Hajam and Rai 2019).

Diabetic men experience reproductive damage, but the mechanisms that cause this damage are still unclear (Ricci et al. 2009; Joshi et al. 2017; He et al. 2021). Diabetes affects the testicular parenchyma by causing a reduction in testicular weight, delay in the seminiferous epithelium cycle, depletion of germ cells, and a reduction in the height of the seminiferous epithelium in animals induced to experimental diabetes (Mallick et al. 2007; Kianifard 2011; Guo et al. 2016).

These changes in the testicular tissue relate to the dysregulation of the hypothalamus-pituitary-gonadal (HPG) axis, usually reported in diabetes, thus reducing the serum levels of essential hormones for good spermatogenic performance, such as the follicle stimulating hormone (FSH), luteinizing hormone (LH), and testosterone (Ballester et al. 2004). FSH regulates Sertoli cells, affects sperm production, and is present at low levels in diabetic individuals (Condorelli et al. 2018). However, there is a decline in LH levels, which regulate the function of Leydig cells and, consequently, promote adverse effects on testosterone production (Ballester et al. 2004).

Testosterone is mostly produced by Leydig cells from the use of cholesterol molecules in a process called steroidogenesis. Normal testosterone levels are crucial for normal spermatogenesis and are directly related to secondary sexual characteristics (Goto et al. 2020). Thus, reductions in testosterone levels are usual in diabetic individuals and may relate to Leydig cell function damage (Ballester et al. 2004; Ricci et al. 2009). Studies indicate a relationship between insulin and Leydig cells, requiring normal levels of this hormone for efficient testosterone production (Ballester et al. 2004).

Therefore, the exogenous insulin protocol is extensively used in diabetic individuals, representing the main form of disease control by reducing blood glucose levels (Rodacki et al. 2022). However, despite studies reporting that insulin therapy improves tubular and sperm parameters (Hajam and Rai 2019; Samadian et al. 2019), studies evaluating Leydig cells are still scarce. Considering that the integrity and functionality of these cells are essential for the normal development of spermatogenesis, this study aimed to assess the effect of administering different insulin concentrations on the morphology of Leydig cells in diabetic individuals.

## 2. Material and Methods

### Experimental Design

Twenty-four adult male Wistar rats (*Rattus norvegicus*, var. *albinus*), 70 days old and weighing 200-300 g, were randomly divided into four groups (n=06): Control Group (CG); Diabetic Group (DG); 50% Insulin (Ins50); 100% Insulin (Ins100). Each group had free access to pelleted food and water until the end of the experiment. They were maintained in a 12-hour reverse light/dark cycle, with controlled humidity (50%) and temperature (22°C), in the vivarium of the Anatomy Department of the Federal University of Pernambuco (UFPE), Brazil. The present study was approved by the Ethics Committee for Animal Experimentation of UFPE (38/12 on 06/11/2013).

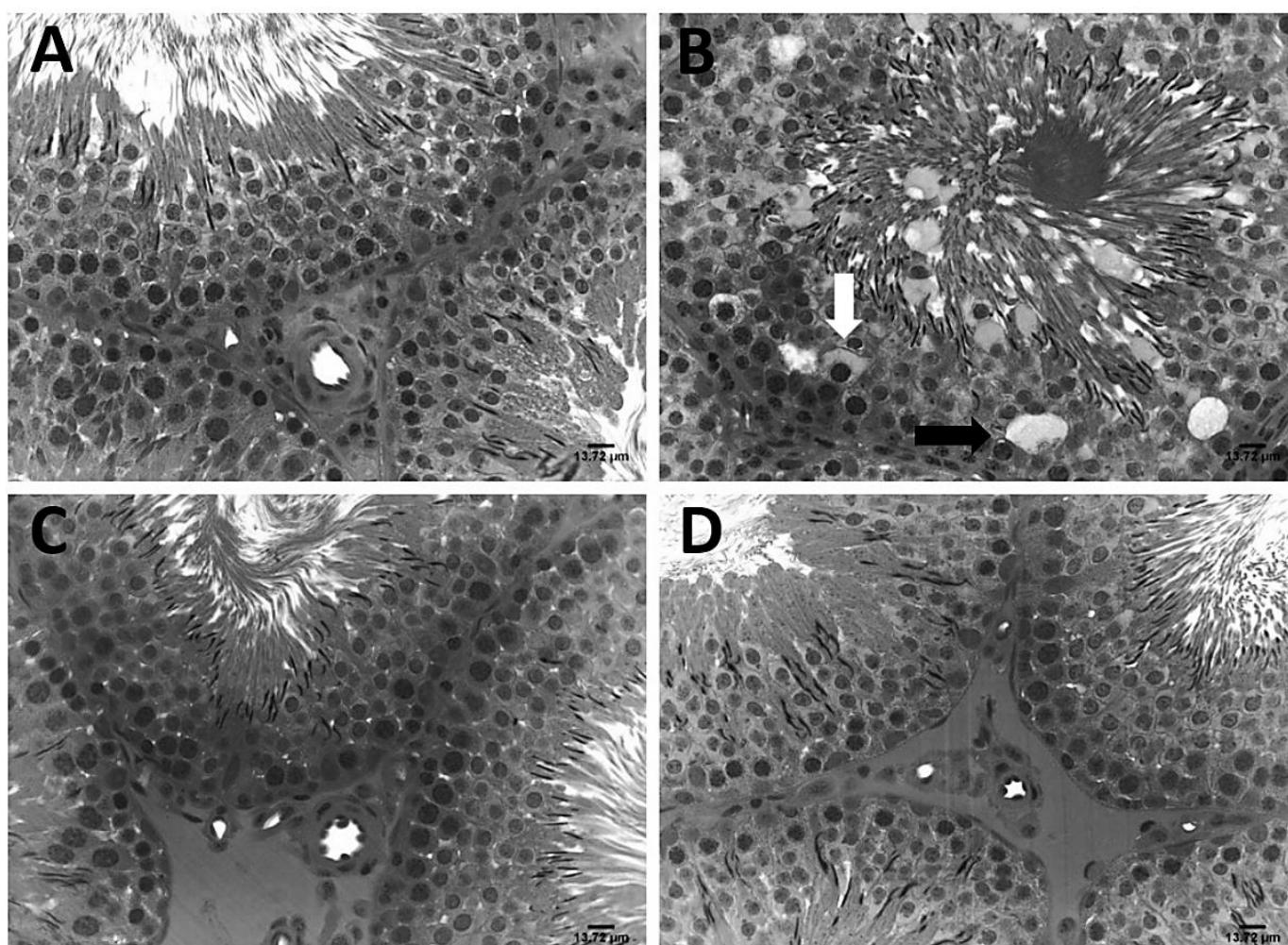
After the rats had fasted for 14 hours, diabetes was induced with a single intraperitoneal injection of streptozotocin (60 mg. Kg<sup>-1</sup>). The Control Group received citrate buffer (vehicle) in the same way. The animals were considered diabetic when they manifested glucose levels above 200 mg.dl<sup>-1</sup>. The glycemic index was verified weekly and before euthanasia by collecting blood from the caudal vein (Glucometer Kit). The diabetic rats were treated with a daily subcutaneous administration (5 UI) of NPH (Neutral Protamine Hagedorn) human insulin. After the onset of diabetes, insulin was administered daily for eight weeks (Gobbo et al. 2015).

Next, the animals were weighed and anesthetized intraperitoneally with ketamine (70 mg/kg) and xylazine (10 mg/kg), followed by deepening of anesthesia with sodium thiopental (80 mg/kg) (Pereira et al. 2018). The animals were subjected to perfusion procedures with a cannula inserted in the left heart ventricle. First, the vessel was cleared with 0.9% NaCl saline solution for two minutes. The animals were then perfused with 4% glutaraldehyde in a phosphate buffer solution for 40 minutes. All testicles were collected, weighed, and post-fixed with the same fixative. The samples were embedded in resin, and 4- $\mu$ m-thick fragments were stained with hematoxylin-phloxine. A quantitative testicular analysis was performed, and the gonadosomatic index (GSI = [testicular weight/body weight] x 100) was calculated (Oliveira et al. 2022).

## Testicular morphometry

### *Volumetric density of testicular compartments*

Volume densities of the testicular parenchyma were obtained with a 441-intersection grid placed under a light microscope. Fifteen randomly chosen sites (6615 points) were scored for each animal at a 400x magnification. The intersection points over the testicular parenchyma tissue were considered as follows: tubular compartment (tunica propria, seminiferous epithelium, and lumen) and intertubular space (Leydig cells, connective tissue, and blood and lymphatic vessels). The volume of each testicular component (ml) was established by Oliveira et al. (2022) (Figure 1).



**Figure 1.** A - Photomicrographs showing the tubular compartment at stage VII. A – control group; B – diabetic group with the vacuoles on seminiferous tubules (black arrow) and the cell death of germination cells (white arrow); C – the diabetic group treated with 50% insulin; D – the diabetic group treated with 100% insulin (400x). Bars: 13.72  $\mu\text{m}$ .

### *Tubular diameter, height of seminiferous epithelium and total length of seminiferous tubules*

Tubular diameter and height of the seminiferous epithelium were measured at a 100x magnification in an image-capture system connected to the light microscope. Fifteen randomly chosen round tubules were measured at various stages of the seminiferous cycle. The rates are the means between two diametrically opposite measurements.

The total length of seminiferous tubules per testis (in meters) was estimated with the ratio between the absolute volume of seminiferous tubules in the testis by  $R^2$  ( $R = \text{tubular diameter}/2$ ) and the  $\pi$  value (Amann and Almquist 1962).

### Score of spermatogenic cells, population of Sertoli cells and daily spermatid production

Spermatogonia, preleptotene/leptotene spermatocyte I, pachytene spermatocyte I, round spermatids, and Sertoli cells nucleoli were counted in five round seminiferous tubules at stage VII in each animal. Then, the number obtained was adjusted (Amann and Almquist 1962).

The mean Sertoli nucleolar cell diameter (5 per animal) was measured at a 1000x magnification, and the population was calculated with the product of the adjusted number of Sertoli cells and the total length of seminiferous tubules in micrometers, divided by slice thickness. Daily sperm production per testis was obtained (Oliveira et al. 2022).

### Nuclear diameter, cell volume and population of Leydig cells

Thirty nuclear profiles were captured at a 1000x magnification and analyzed. The nuclear diameter was obtained with two diametrically opposite measurements (Oliveira et al. 2022). The volumetric density (%) of Leydig cells was measured with a 441-point reticule (locked to the microscope) at a 1000x magnification. One thousand points were counted, including the nucleus and cell cytoplasm. The volume of each Leydig cell was determined with mathematical models by nuclear diameter rates and proportion in the testis (Oliveira et al. 2022). The Leydig cell population was obtained with volume rates of each cell, volumetric density (%), and total volume (ml) occupied by Leydig cells in the testis.

### Plasma testosterone

Testosterone was quantified with enzyme immunoassay (Munro et al. 1991) using a polyclonal anti-testosterone antibody (R 156/7 1:7500 dilution) obtained from Coralie Munro University of California, Davis (Davis, CA, USA).

### Statistical analysis

The results were blinded to normality assumptions with the Kolmogorov-Smirnov test and subjected to base-10 logarithmic transformation and ANOVA, with the GLM procedure in the SAS software (Statistical Analysis Systems Institute Inc). Means were compared with the minimum significant difference (m.s.d.) of the Student-Newman-Keuls (SNK) test at a 5% significance level. Testosterone was subjected to logarithmic transformation, and Pearson's correlation analyses ( $r$ ) were performed to verify relationships among variable pairs (Preece and Hills 1982). High-intensity correlation occurred when  $r > 0.60$ , medium intensity when  $0.30 < r < 0.60$ , and low intensity when  $r < 0.30$ .

## 3. Results

Table 1 shows a body weight reduction in untreated diabetic rats (46%) compared to animals in the control group. In the insulin-treated group, body weight increased significantly but remained lower than that of the control group. Testicular weight also showed a significant decrease in the diabetic group compared to the control group. In insulin-treated groups, this parameter was recovered compared to diabetic rats.

**Table 1.** Glycemic index, body weight, testicular weight, and gonadosomatic index (GSI) of control, diabetic, and insulin-treated Wistar rat groups.

	Control	Diabetic	Ins50	Ins100	P value
Glycaemia (mg/dL)	88.50±10.44 <sup>c</sup>	425.17±48.62 <sup>a</sup>	291±18.08 <sup>b</sup>	104.17±21.92 <sup>c</sup>	p<0.0001
Body Weight (g)	336.7±42.51 <sup>a</sup>	180.0±22.16 <sup>c</sup>	275.67±32.09 <sup>b</sup>	316.0±29.61 <sup>a</sup>	p<0.0001
Testicular Weight (g)	1.53±0.08 <sup>a</sup>	1.17±0.24 <sup>b</sup>	1.45±0.11 <sup>a</sup>	1.634±0.14 <sup>a</sup>	p= 0.0002
GSI (%)	0.91±0.079 <sup>c</sup>	1.28±0.120 <sup>a</sup>	1.05±0.106 <sup>b</sup>	1.03±0.072 <sup>b</sup>	p<0.0001

Different letters on the same line indicate statistical difference.

Table 2 shows tubular parameter rates. There were no differences in the tubular diameter of seminiferous tubules among the experimental groups. Epithelium height, tubular volume, and the length of seminiferous tubules in the diabetic group decreased in untreated diabetic rats compared to control rats. There were no changes in the population of Sertoli cells, the number of round spermatids, and Sertoli cells/cross-section among the experimental groups. Daily sperm production of the testis tended to decrease by 19% and 15% in the diabetic group compared to the control and INS50 groups, respectively. However, these parameters increased significantly in animals of the INS100 group compared to diabetic rats. Figure 1 shows photomicrographs of the tubular compartment at stage VII in untreated diabetic animals, with vacuolization in Sertoli cells compatible with the start of testicular degeneration.

**Table 2.** Parameters of the tubular compartment of control, diabetic, and insulin-treated groups.

	Control	Diabetic	Ins50	Ins100	P value
Tubular Diameter ( $\mu\text{m}$ )	339.79 $\pm$ 31.86 <sup>a</sup>	320.34 $\pm$ 23.71 <sup>a</sup>	328.86 $\pm$ 16.61 <sup>a</sup>	329.14 $\pm$ 18.68 <sup>a</sup>	p=0.4516
Epithelium Height ( $\mu\text{m}$ )	116.17 $\pm$ 6.52 <sup>a</sup>	102.86 $\pm$ 11.34 <sup>b</sup>	110.37 $\pm$ 6.41 <sup>ab</sup>	104.80 $\pm$ 4.53 <sup>b</sup>	p=0.0287
Tubular Volume (ml)	1.35 $\pm$ 0.06 <sup>a</sup>	1.06 $\pm$ 0.19 <sup>b</sup>	1.28 $\pm$ 0.10 <sup>a</sup>	1.43 $\pm$ 0.11 <sup>a</sup>	p=0.0004
Length of ST (m)	14.83 $\pm$ 1.95 <sup>ab</sup>	12.76 $\pm$ 1.19 <sup>b</sup>	15.11 $\pm$ 2.49 <sup>ab</sup>	16.9 $\pm$ 1.76 <sup>a</sup>	p=0.0113
Sertoli Cells ( $\times 10^6$ )	33.73 $\pm$ 5.64 <sup>a</sup>	33.87 $\pm$ 6.85 <sup>a</sup>	37.14 $\pm$ 10.50 <sup>a</sup>	39.89 $\pm$ 4.99 <sup>a</sup>	p=0.4252
Round Spermatids	84.39 $\pm$ 5.05 <sup>a</sup>	82.20 $\pm$ 4.44 <sup>a</sup>	77.36 $\pm$ 13.26 <sup>a</sup>	86.14 $\pm$ 2.76 <sup>a</sup>	p=0.2414
Sertoli cells/cross section	9.18 $\pm$ 1.58 <sup>a</sup>	10.61 $\pm$ 1.89 <sup>a</sup>	9.73 $\pm$ 1.63 <sup>a</sup>	9.52 $\pm$ 1.55 <sup>a</sup>	p=0.5103
Daily Sperm Production ( $\times 10^6$ )	25.98 $\pm$ 6.61 <sup>ab</sup>	20.66 $\pm$ 2.87 <sup>b</sup>	24.21 $\pm$ 6.15 <sup>ab</sup>	30.06 $\pm$ 2.30 <sup>a</sup>	p=0.025

Different letters on same line indicate statistical difference.

Table 3 shows that testosterone levels decreased (47%) in DG compared to CG. After insulin treatment, testosterone levels increased significantly compared to those in DG. The nuclear diameter and volume of Leydig cells decreased in DG compared to CG. After insulin administration, these parameters were recovered in the Ins50 and Ins100 groups. Nevertheless, the population of Leydig cells tended to increase by 39% in diabetic animals compared to CG. However, the number of Leydig cells after insulin therapy was not different from that in CG. Figure 2 shows photomicrographs of interstitial compartments with a reduction of the nuclear volume of Leydig cells in untreated diabetic animals.

**Table 3.** Parameters of Leydig cells in control, diabetic, and insulin-treated groups.

	Control	Diabetic	Ins50	Ins100	P value
Testosterone (nMol/L)	1.03 $\pm$ 0.61 <sup>b</sup>	0.48 $\pm$ 0.22 <sup>b</sup>	6.33 $\pm$ 5.01 <sup>a</sup>	6.63 $\pm$ 6.01 <sup>a</sup>	p=0.0028
Interstitial Volume (mL)	0.08 $\pm$ 0.007 <sup>a</sup>	0.06 $\pm$ 0.011 <sup>b</sup>	0.09 $\pm$ 0.011 <sup>a</sup>	0.09 $\pm$ 0.015 <sup>a</sup>	p<0.0001
Nuclear Diameter of Leydig ( $\mu\text{m}$ )	7.09 $\pm$ 0.36 <sup>a</sup>	5.94 $\pm$ 0.99 <sup>b</sup>	7.48 $\pm$ 0.33 <sup>a</sup>	7.77 $\pm$ 0.25 <sup>a</sup>	p=0.0001
Volume of Leydig cells ( $\mu\text{m}^3$ )	660.6 $\pm$ 104.72 <sup>b</sup>	400.6 $\pm$ 173.2 <sup>c</sup>	566.6 $\pm$ 94.47 <sup>b</sup>	809.7 $\pm$ 93.9 <sup>a</sup>	p<0.0001
Population of Leydig cells ( $\times 10^6$ )	36.49 $\pm$ 9.56 <sup>a</sup>	50.6 $\pm$ 14.42 <sup>a</sup>	39.4 $\pm$ 12.46 <sup>a</sup>	41.5 $\pm$ 12.46 <sup>a</sup>	p=0.2528

Different letters on same line indicate statistical difference.

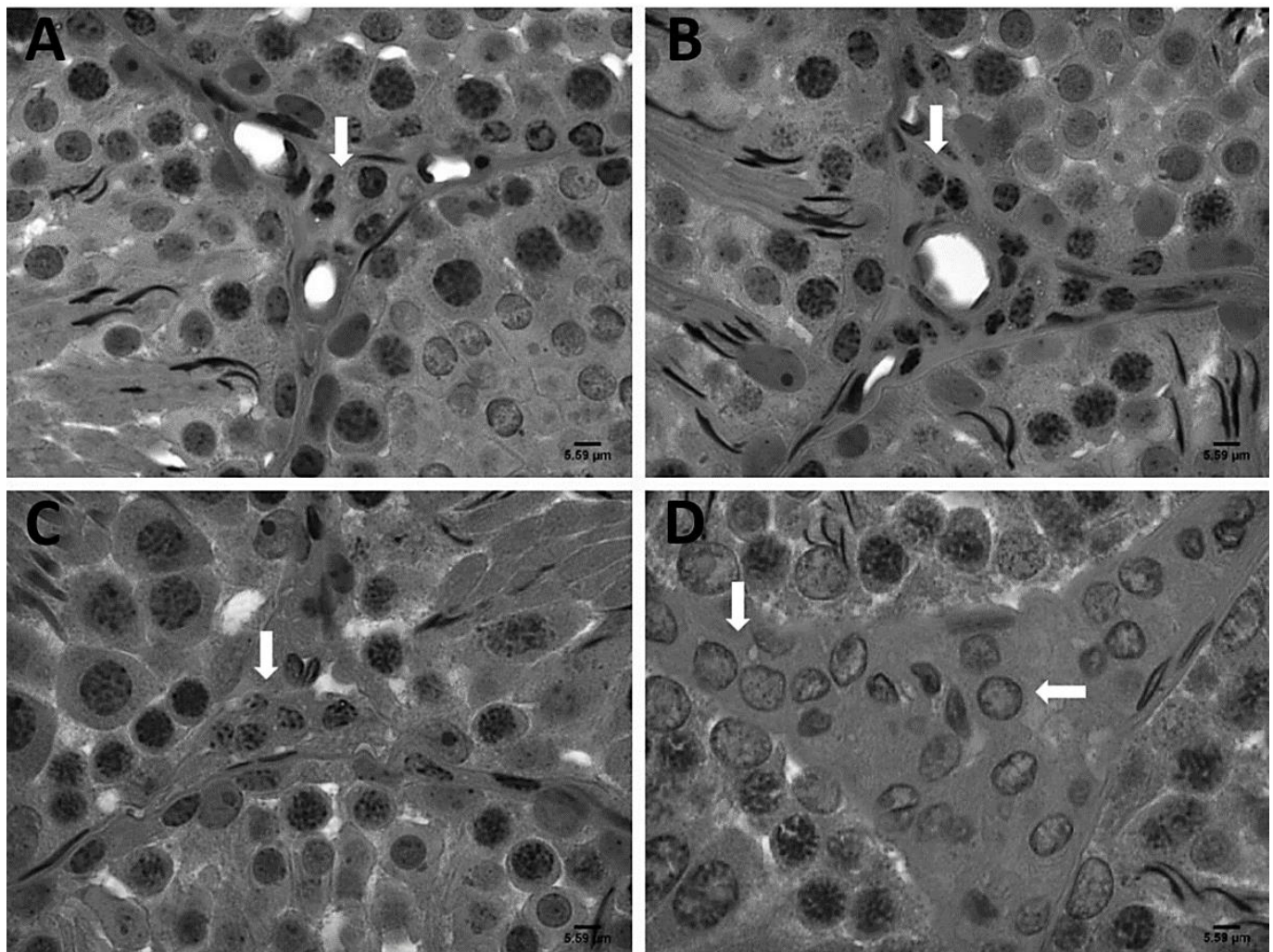
According to the correlation test, glycemia had a high negative correlation to testicular weight ( $r=-0.72$ ;  $p<0.0001$ ), tubular volume ( $r=-0.71$ ;  $p<0.0001$ ), the volume of Leydig cells ( $r=-0.70$ ;  $p<0.0001$ ), the nuclear diameter of Leydig cells ( $r=-0.60$ ;  $p<0.0021$ ) and body weight ( $r=-0.89$ ;  $p<0.0001$ ) (Figure 1). However, the same parameter had a strong positive correlation to the gonadosomatic index ( $r=0.73$ ;  $p<0.0001$ ). Diabetic animals had a mean negative correlation between plasma glucose levels and the total length of seminiferous tubules ( $r=-0.55$ ;  $p<0.0056$ ), daily sperm production ( $r=-0.57$ ;  $p<0.0035$ ), the population of Leydig cells ( $r=-0.42$ ;  $p<0.0398$ ) and testicular interstitial volume ( $r=-0.54$ ;  $p<0.0059$ ) (Figure 3).

#### 4. Discussion

Insulin therapy is one of the main means of controlling blood glucose levels in diabetic individuals. Nonetheless, the influence of insulin on the morphofunctional aspects of Leydig cells has not been explored. This study showed that high glucose levels promoted a negative interference in testicular parameters such as the volumetric density of seminiferous tubules, nuclear diameter and volume of Leydig cells, testosterone levels, and daily sperm production. Insulin application at different concentrations was

imperative to analyze the impact of this hormone on the recovery of damages in the testicular parenchyma of diabetic individuals.

The results showed a negative correlation between body weight and hyperglycemia. The reduction in body mass is extensively reported in animals subjected to experimental diabetes (Ballester et al. 2004), which may be associated with excessive water loss through urine and decreased protein levels, typical of the development of this pathology (Yared and Chiasson 2003; Hajam and Rai 2019). Furthermore, insulin stimulates lipogenesis; therefore, low levels of this hormone can activate lipases, fat mobilization, breakdown of triglycerides, and a consequent release of fatty acids (Yared and Chiasson 2003; Long et al. 2018). Therefore, diabetic animals treated with insulin experienced increased body weight and a reduction of fasting glucose levels proportional to the administered dose, efficiently recovering these parameters.



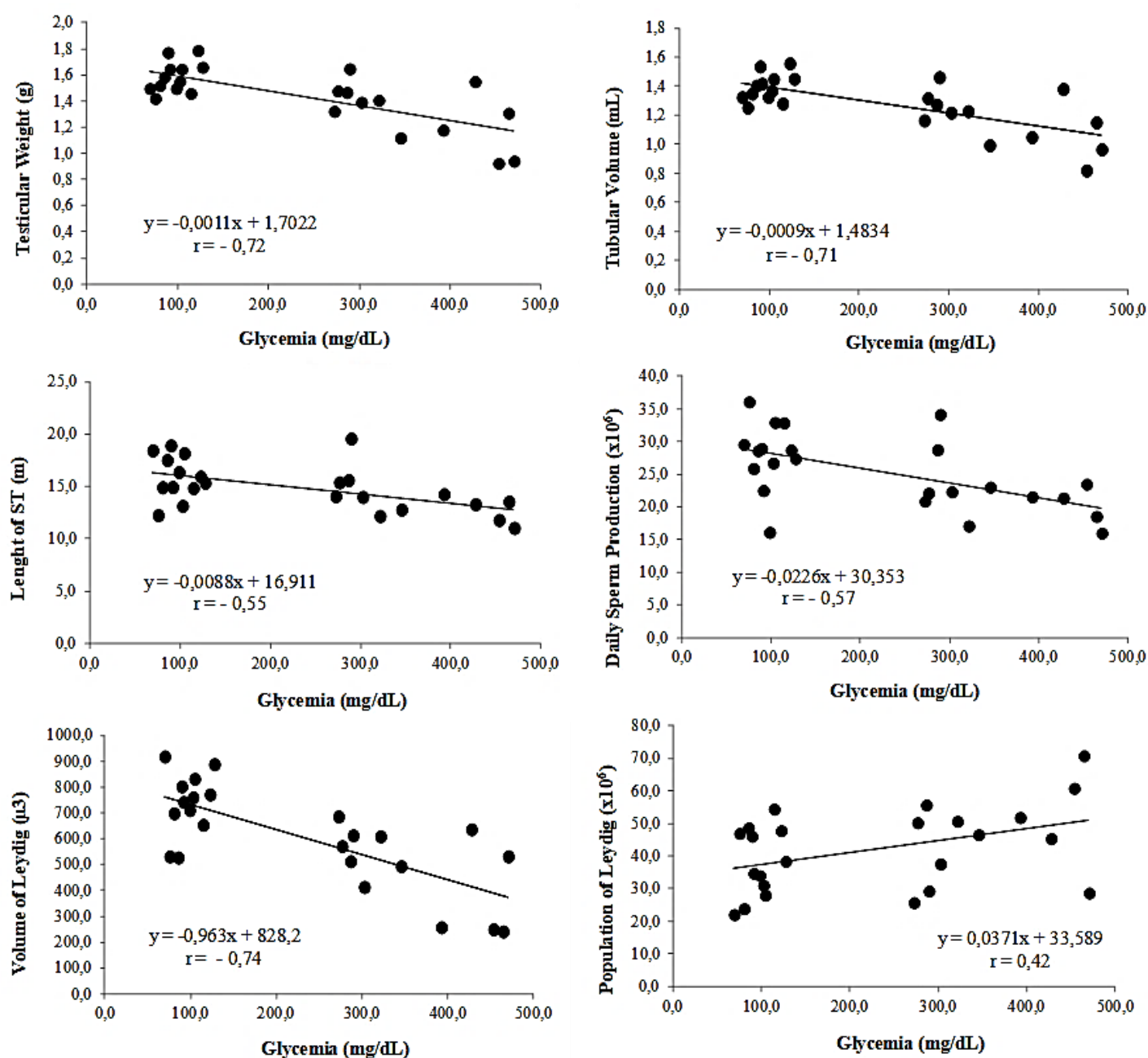
**Figure 2.** Photomicrographs showing the intertubular compartment. A – control group; B – diabetic group with reduction of the nuclear volume of Leydig cells (white arrow); C – diabetic group treated with 50% insulin; D – diabetic group treated with 100% insulin, note the nuclear volume of Leydig cells (white arrow) increased after insulin therapy (1000x). Bars: 5.59 µm.

However, the reduction in testicular mass, already reported in previous experiments with diabetes-induced rats (Ballester et al. 2004; Kianifard 2011), was also verified in the present experiment. The drop in testicular weight is a type of initial macroscopic evaluation, having a direct relationship with the sperm production of the animals. Moreover, plasma insulin levels influence the weight of testicles, which decreased in mice without insulin receptors (Griffeth et al. 2013). In this experiment, the administration of exogenous insulin increased testicular weight in rats according to the applied dose, showing the influence of administering the hormone on these biometric data.

The Gonadosomatic Index (GSI) is a mathematical ratio that indicates the percentage of body weight allocated to the testicles (Boonkusol et al. 2020) and is directly related to the comparative sperm production in rodents (Siman et al. 2017). Unlike body weight, blood glucose is positively correlated to GSI,

showing high levels in diabetic animals due to a disproportionate drop in body and testicular weight. The use of exogenous insulin reduced glucose levels and increased body and testicular weight, consequently decreasing GSI.

Low testosterone levels compromise reproductive performance because this hormone is vital in regulating the seminiferous epithelium cycle and relates to secondary sexual characters (Schoeller et al. 2012). Previous studies with diabetes-induced rats also showed reductions in testosterone levels and the tubular architecture of animals, such as reduction of the tubular diameter and height of the epithelium, increased apoptosis in germ cells, and delays in the spermatogenic process (Ricci et al. 2009; Trindade et al. 2013). Therefore, the drop in testosterone levels may have been a reflection of the reductions in tubular volumetric density, the height of the seminiferous epithelium, and the length of the seminiferous tubules, which were also observed in the present experiment. Insulin therapy recovered these tubular parameters and increased serum testosterone levels, emphasizing the role of exogenous insulin in the seminiferous epithelium cycle.



**Figure 3.** Pearson’s correlation (r) between plasma glucose concentration (mg/dL) with different testicular parameters of control, diabetic and insulin-treated groups.

This study did not show significant differences in the population of Sertoli cells, but the daily sperm production decreased in untreated diabetic animals. Additionally, these animals showed a significant amount of vacuoles in Sertoli and germ cells, which may relate to the reduction in sperm production. Besides the responsibility for nourishing and supporting germ cells, the number of Sertoli cells determines the daily sperm production in sexually mature animals, functioning according to normal FSH concentrations (He et al. 2021). Low FSH levels have been reported in animals induced to experimental diabetes (Ballester et al. 2004); therefore, these changes may have occurred due to the strong negative correlation of high glucose levels with testicular weight, seminiferous epithelium height, seminiferous tubule length, and volumetric density of the tubular compartment.

However, it has already been described in a study with diabetic mice that low levels of insulin can compromise the functionality of Sertoli cells through interference in the regulation and expression of insulin receptors in these cells, leading to reduced testicular size and low sperm production (Maresch et al. 2017). According to the present experiment, the glycemic control performed by different insulin doses recovered 17% and 45% of the daily sperm production, in the groups with the lowest dose and the highest insulin dose, respectively.

The reduction in volumetric tubular density and height of the seminiferous epithelium may also relate to an increase in Leydig cells in the interstitial compartment as a compensatory response to changes in hormonal levels. According to Ricci et al. (2009), damage to spermatogenesis is directly related to changes in the functionality of Leydig cells, in both the reduction of testosterone levels and its irregular distribution in the testicular interstitial compartment. In diabetic animals, these cells increased by 49%, as reported by some authors (Sanguinetti et al. 1995; Hassen et al. 2007). However, other studies have recorded reductions in the population of these cells (Ballester et al. 2004; Ballester et al. 2005; Abbasi et al. 2013) or no changes in their number in the interstitial space (Cameron et al. 1985). This variation can be due to several factors, such as induction protocol, experimental time, or differences among the studied species.

However, there were also reductions in the nuclear diameter and individual volume of Leydig cells in untreated diabetic animals. This result may relate to the drop in gonadotropin and testosterone levels (Mallick et al. 2007). In this sense, Leydig cells consist of a smooth endoplasmic reticulum (SER) in a large portion of the cytoplasmic area, containing essential enzymes for steroidogenesis (Kianifard 2011). Therefore, cell volume reductions may relate to a lower number of SER, compromising androgen production. A study with spontaneously diabetic rats (BB/OKL) reported reductions in steroidogenic enzyme levels that affected Leydig cell function and differentiation due to an increase in the inflammatory state with elevations in TNF-alpha levels.

Also, the absence of normal insulin levels affects the endocrine control of spermatogenesis and the function of testosterone-producing cells, which can compromise reproductive performance (Bruning et al. 2000; Schoeller et al. 2012). Reductions in LH levels and the number of Leydig cells have been verified in rats with mutations in brain insulin receptors, showing the negative interference of low insulin levels with reproduction (Bruning et al. 2000). Therefore, insulin administration effectively reduced the population of Leydig cells in the interstitial space resulting from the increased nuclear diameter and individual cell volume. The restoration of testosterone levels, which was also observed, may relate to improvements in the functionality of these cells, as seen in a study with transgenic mice subjected to insulin therapy (Schoeller et al. 2012). According to Wagner et al. (2021), spontaneously diabetic rats subjected to short-term insulin therapy for six weeks had high levels of steroidogenic enzymes and consequent elevations in serum testosterone levels. Therefore, after eight weeks of insulin therapy in the present experiment, testosterone levels increased, indicating that, in the long term, insulin replacement was effective for Leydig cell stimulation and functionality.

## **5. Conclusions**

The negative changes observed in the testicular parenchyma from the establishment of diabetes may relate to hormonal failures and structural and functional changes in testosterone-producing cells, compromising the performance of spermatogenesis. The treatment with exogenous insulin in different



doses was efficient in recovering testicular parameters proportional to the administered concentration, indicating that controlling plasma glucose with the recovery of normal insulin levels is essential to maintaining the reproductive quality of diabetic animals.

**Authors' Contributions:** SILVA, A.A.N.: conception and design, acquisition of data, analysis and interpretation of data and drafting and the article; DE OLIVEIRA, J.S.: analysis and interpretation of data, critical review of important intellectual content and drafting the article; DIAS, F.C.R.: critical review of important intellectual content and drafting the article; DE MORAES, R.N.: acquisition of data; DE MELO, E.N.: acquisition of data; SOARES, P.C.: acquisition of data; DA SILVA JUNIOR, V.A.: analysis and interpretation of data, critical review of important intellectual content and drafting the article. All authors have read and approved the final version of the manuscript.

**Conflicts of Interest:** The authors declare no conflicts of interest.

**Ethics Approval:** The current study was approved by the Committee for Ethics in Animal Experimentation of the UFPE (38/12 on 06/11/2013).

**Acknowledgments:** The study was financed in part by the Coordenação de Aperfeiçoamento de Pessoal de Nível Superior – Brasil (CAPES) – Finance Code 001 and a PhD scholarship provided to FCRD, Fundação de Amparo à Ciência e Tecnologia de Pernambuco (FACEPE/BFP-0002-5/21).

## References

- ABBASI, Z., et al. Effects of Sesame Oil on the Reproductive Parameters of Diabetes Mellitus-Induced Male Rats. *The World Journal of Men's Health*. 2013, **31**(2), 141 <https://doi.org/10.5534/wjmh.2013.31.2.141>
- AMANN, R.P. and ALMQUIST, J.O. Reproductive Capacity of Dairy Bulls. VIII. Direct and Indirect Measurement of Testicular Sperm Production. *Journal of Dairy Science*. 1962, **45**(6), 774–781. [https://doi.org/10.3168/jds.S0022-0302\(62\)89487-9](https://doi.org/10.3168/jds.S0022-0302(62)89487-9)
- BALLESTER, J., et al. Insulin-Dependent Diabetes Affects Testicular Function by FSH- and LH-Linked Mechanisms. *Journal of Andrology*. 2004, **25**(5), 706–719. <https://doi.org/10.1002/j.1939-4640.2004.tb02845.x>
- BALLESTER, J., et al. Tungstate treatment improves Leydig cell function in streptozotocin- diabetic rats. *Journal of Andrology*. 2005, **26**(6), 706–715. <https://doi.org/10.2164/jandrol.04156>
- BOONKUSOL, D., JUNSHUM, P. and PANPROMMIN, K. Gonadosomatic Index, Oocyte Development and Fecundity of the Snakehead Fish (*Channa striata*) in Natural River of Mae La, Singburi Province, Thailand. *Pakistan Journal of Biological Science*. 2020, **23**(1), 1-8. <https://doi.org/10.3923/pjbs.2020.1.8>.
- BRUNING, J.C., et al. Role of Brain Insulin Receptor in Control of Body Weight and Reproduction. *Science*, 2000, **289**(5487), 2122-2125. <https://doi.org/10.1126/science.289.5487.2122>
- CAMERON, D.F., MURRAY, F.T. and DRYLIE, D.D. Interstitial compartment pathology and spermatogenic disruption in testes from impotent diabetic men. *The Anatomical Record*. 1985, **213**(1), 53–62. <https://doi.org/10.1002/ar.1092130108>
- CONDORELLI, R.A., et al. Diabetes Mellitus and Infertility: Different Pathophysiological Effects in Type 1 and Type 2 on Sperm Function. *Frontiers in Endocrinology (Lausanne)*. 2018, **9**, 268. <https://doi.org/10.3389/fendo.2018.00268>
- GOBBO, M.G., et al. Effect of Melatonin Intake on Oxidative Stress Biomarkers in Male Reproductive Organs of Rats under Experimental Diabetes. *Oxidative Medicine and Cellular Longevity*. 2015, **2015**, 1-12. <https://doi.org/10.1155/2015/614579>
- GOTO, T., et al. Testosterone Supplementation Rescues Spermatogenesis and In Vitro Fertilizing Ability of Sperm in Kiss1 Knockout Mice. *Endocrinology*. 2020, **161**(9), bqaa092. <https://doi.org/10.1210/endocr/bqaa092>
- GRIFFETH, R.J., CARRETERO, J. and BURKS, D.J. Insulin Receptor Substrate 2 Is Required for Testicular Development. *PLoS ONE*. 2013, **8**(5), 119-129. <https://doi.org/10.1371/journal.pone.0062103>
- GUO, Z., et al. Effect of Telmisartan or Insulin on the Expression of Adiponectin and its Receptors in the Testis of Streptozotocin-Induced Diabetic Rats. *Hormone and Metabolic Research*. 2016, **48**(6), 404–412. <https://doi.org/10.1055/s-0042-101549>
- HAJAM, Y.A. and RAI, S. Melatonin and insulin modulates the cellular biochemistry, histoarchitecture and receptor expression during hepatic injury in diabetic rats. *Life Sciences*. 2019, **239**, 117046. <https://doi.org/10.1016/j.lfs.2019.117046>
- HASSEN, N.S., ROUBI, N.M.E.I. and OMARA, E.A. Evaluation of the Influence of each of Melatonin and Chromium against Diabetes-Induced Alteration in the Testis of Albino Rats Using Light and Electron Microscopies. *The Egyptian Journal of Hospital Medicine*. 2007, **27**(1), 143–162. <https://doi.org/10.12816/ejhm.2007.17718>
- HE, Z., et al. Diabetes Mellitus Causes Male Reproductive Dysfunction: A Review of the Evidence and Mechanisms. *In Vivo*. 2021, **35**(5), 2503-2511. <https://doi.org/10.21873/invivo.12531>

- JOSHI, D., SARKAR, D. and SINGH, S. K. Decreased expression of orexin 1 receptor in adult mice testes during alloxan-induced diabetes mellitus perturbs testicular steroidogenesis and glucose homeostasis. *Biochemical and Biophysical Research Communications*. 2017, **490**(4), 1346–1354. <https://doi.org/10.1016/j.bbrc.2017.07.026>
- KIANIFARD, D. The Histological, Histomorphometrical and Histochemical Changes of Testicular Tissue in the Metformin Treated and Untreated Streptozotocin-Induced Adult Diabetic Rats. *Veterinary Research Forum*. 2011, **2**(1), 13–24.
- LONG, L., et al. Hyperglycemia induced testicular damage in type 2 diabetes mellitus rats exhibiting microcirculation impairments associated with vascular endothelial growth factor decreased via PI3K/Akt pathway. *Oncotarget*. 2018, **9**(4), 5321–5336. <https://doi.org/10.18632/oncotarget.23915>
- MALLICK, C., et al. Protection of Testicular Dysfunctions by MTEC, a Formulated Herbal Drug, in Streptozotocin Induced Diabetic Rat. *Biological & Pharmaceutical Bulletin*. 2007, **30**(1), 84–90. <https://doi.org/10.1248/bpb.30.84>
- MARESCH, C. C., et al. Hyperglycemia is associated with reduced testicular function and activin dysregulation in the Ins2Akita+/- mouse model of type 1 diabetes. *Molecular and Cellular Endocrinology*. 2017, **446**, 91–101. <https://doi.org/10.1016/j.mce.2017.02.020>
- MARESCH, C.C., et al. Diabetes-induced hyperglycemia impairs male reproductive function: a systematic review. *Human Reproductive Update*. 2018, **24**(1), 86–105. <https://doi.org/10.1093/humupd/dmx033>
- MUNRO, C.J., et al. Relationship of serum estradiol and progesterone concentrations to the excretion profiles of their major urinary metabolites as measured by enzyme immunoassay and radioimmunoassay. *Clinical Chemistry*. 1991, **37**(6), 838–844. <https://doi.org/10.1093/clinchem/37.6.838>
- OLIVEIRA, J.S., et al. Histomorphometric and oxidative evaluation of the offspring's testis from type 2 diabetic female rats treated with metformin and pentoxifylline. *International Journal of Experimental Pathology*. 2022, **2022**, 1–16. <https://doi.org/10.1111/iep.12446>
- PEREIRA, A.S.B.F, et al. Metformin Hydrochloride-Loaded PLGA Nanoparticle in Periodontal Disease Experimental Model Using Diabetic Rats. *International Journal of Molecular Sciences*. 2018, **19**(11):3488. <https://doi.org/10.3390/ijms19113488>
- PREECE, D.A., LITTLE, T.M. and HILLS, F.J. Agricultural Experimentation: Design and Analysis. *Biometrics*. 1982, **38**(2), 524. <https://doi.org/10.2307/2530470>
- RICCI, G., et al. Diabetic rat testes : morphological and functional alterations. *Andrologia*. 2009, **41**(6), 361–368.
- RODACKI, M., et al. Classificação do diabetes. Diretriz Oficial da Sociedade Brasileira de Diabetes (2022). <https://doi.org/10.29327/557753.2022-1>
- SAMADIAN, Z., et al. Moderate-intensity exercise training ameliorates the diabetes-suppressed spermatogenesis and improves sperm parameters: Insole and simultaneous with insulin. *Andrologia*. 2019, **51**(11), 1–11. <https://doi.org/10.1111/and.13457>
- SANGUINETTI, R.E., et al. Ultrastructural Changes in Mouse Leydig Cells after Streptozotocin Administration. *Experimental Animals*. 1995, **44**(1), 71–73. <https://doi.org/10.1538/expanim.44.71>
- SCHOELLER, E.L., et al. Insulin rescues impaired spermatogenesis via the hypothalamic-pituitary- gonadal axis in Akita diabetic mice and restores male fertility. *Diabetes*. 2012, **61**(7), 1869–1878. <https://doi.org/10.2337/db11-1527>
- SIMAN, V.A., et al. Spermatogenic dynamics of the spiny rat *Kannabateomys amblyonyx* (Wagner, 1845) (Rodentia, Echimyidae). *Animal Reproduction Science*. 2017, **184**, 36–43. <https://doi.org/10.1016/j.anireprosci.2017.06.011>.
- TRINDADE, A.A.T., et al. Long term evaluation of morphometric and ultrastructural changes of testes of alloxan-induced diabetic rats. *Acta Cirurgica Brasileira*. 2013, **28**(4), 256–265. <https://doi.org/10.1590/S0102-86502013000400005>
- WAGNER, I.V., et al. Diabetes Type 1 Negatively Influences Leydig Cell Function in Rats, Which is Partially Reversible By Insulin Treatment. *Endocrinology*. 2021, **162**(4), bqab017. <https://doi.org/10.1210/endo/bqab017>
- YARED, Z. and CHIASSON, J.L. Ketoacidosis and the hyperosmolar hyperglycemic state in adult diabetic patients: Diagnosis and treatment. *Minerva Medica*. 2003, **94**(6), 409–418.

Received: 16 April 2022 | Accepted: 28 August 2022 | Published: 10 March 2023



This is an Open Access article distributed under the terms of the Creative Commons Attribution License, which permits unrestricted use, distribution, and reproduction in any medium, provided the original work is properly cited.