









DOXYCYCLINE HYCLATE MAY DAMAGE TESTICULAR  
GERMINAL EPITHELIUM IN WISTAR RATS

João Vitor LOPES-FERREIRA<sup>1</sup> , Jullyana Costa MACHADO<sup>1</sup> , Fernanda Carolina Ribeiro DIAS<sup>1,2</sup> ,  
Luciana Schulthais ALTOÉ<sup>3</sup> , Reggiani Gonçalves VILELA<sup>3</sup> , Sérgio Luis Pinto DA MATTA<sup>4</sup> ,  
Angelica de Oliveira GOMES<sup>1</sup> , Marcos de Lucca Moreira GOMES<sup>1</sup> 

<sup>1</sup>Laboratory of Cell Interactions, Universidade Federal do Triângulo Mineiro, Uberaba, Minas Gerais, Brazil.

<sup>2</sup>Universidade Federal Rural de Pernambuco, Recife, Pernambuco, Brazil.

<sup>3</sup>Department of Animal Biology, Universidade Federal de Viçosa, Viçosa, Minas Gerais, Brazil.

<sup>4</sup>Department of General Biology, Universidade Federal de Viçosa, Minas Gerais, Brazil.

**Corresponding author:**

Marcos de Lucca Moreira Gomes  
marcos.gomes@uftm.edu.br

**How to cite:** LOPES-FERREIRA, J.V., et al. Doxycycline hyclate may damage testicular germinal epithelium in Wistar rats. *Bioscience Journal*. 2023, **39**, e39031. <https://doi.org/10.14393/BJ-v39n0a2023-64399>

**Abstract**

Broad-spectrum antimicrobial doxycycline acts as an inhibitor of protein synthesis and it is widely used in the clinical treatment of various infections by microorganisms that are sensitive to the drug, as well as in animal feed. Its liposolubility guarantees its high tissue bioavailability, being associated with several biochemical changes in the organism and potentially adverse effects on reproduction. This study aims to evaluate the effects of the action of doxycycline on spermatogenesis to provide a complete analysis of the tubular and interstitial compartments and to identify possible changes in the testicular parenchyma. Adult male Wistar rats were divided into three groups: one control (water), and two treated with doxycycline at the doses of 10mg/kg and 30mg/kg, for 30 days. After euthanasia and sample processing, the following parameters were evaluated: a) tubular diameter and height of the seminiferous epithelium; b) volumetric proportions (%) and volumes (mL) of the components of the testicular parenchyma; c) counting testicular germ cell populations; d) evaluation of cell viability. The results of the comparative evaluation between the experimental groups demonstrated a significant increase in the diameter and area of the tubular lumen and a reduction in the count of spermatogonia in the experimental group that received doxycycline hyclate at a dose of 30mg/kg. In the same experimental group, an increase in the overall yield of spermatogenesis was found as a consequence of the increase in the mitotic index.

**Keywords:** Antibiotics. Histology. Male Infertility. Morphometry. Reproduction.

**1. Introduction**

Doxycycline (alpha-6-deoxy oxytetracycline) is a second-generation broad-spectrum tetracycline-class antibiotic, a semi-synthetic derivative of oxytetracycline (Holmes and Charles 2009). Clinically, doxycycline is effective in the first-line treatment of infections caused by a wide range of Gram positive and Gram negative bacteria, including atypical microorganisms such as *Rickettsia* spp, *Mycoplasma pneumoniae*, *Haemophilus influenzae*, *Chlamydia trachomatis* and *Borrelia burgdorferi* (Holmes and Charles 2009). It is also used as an adjuvant in the treatment of intestinal amoebiasis (Cortez-Maya et al. 2020), acne (Zaenglein et al. 2016), *Plasmodium falciparum* malaria (Nodari et al. 2020), leptospirosis (Le

Turnier and Epelboin 2018) and cholera. In addition, doxycycline is commonly used in veterinary medicine for the treatment of infections and as an addition to animal feed as a means of increasing the growth rate (Landers et al. 2012).

Doxycycline has bacteriostatic action, crossing the cell membrane and inhibiting protein synthesis in a wide spectrum of microorganisms by reversibly binding to the 30S subunit of the ribosome and blocking the access of aminoacyl-tRNA to the complex (Chopra and Roberts 2001). Furthermore, it can inhibit the action of extracellular matrix metalloproteinases (Skúlason et al., 2003). Moreover, doxycycline is capable of disturbing steroidogenesis in therapeutic doses, which results in testosterone deficiency and decreased sperm quality in mice exposed to the drug (Hou et al. 2019). Therefore, antimicrobials from the tetracycline class may be directly associated with significant damage to male fertility.

Several studies have been performed regarding the effects of antimicrobials of the tetracycline class on the male reproductive system. In 1967, the ability to bind tetracyclines to mammalian sperm was demonstrated (Ericsson and Baker 1967). Irreversible damage to sperm motility was observed after the addition of low doses (2.5 µg/ml) of tetracycline to sperm *in vitro* (Hargreaves et al. 1998). The evaluation of sperm parameters after treatment with tetracycline, such as epididymal sperm motility, viability and morphology, as well as the histopathology of the testicular parenchyma and testosterone production were impaired. Furthermore, a reduction in the relative weights of the testes, epididymis and seminal vesicles was observed (Farombi et al. 2008).

The exposure to anthropogenic agents, such as antibiotics, with potential deleterious effects on the male reproductive system can be associated with male infertility. Due to the wide use of doxycycline and its possible adverse effects on the testicular parenchyma, a complete scan of important testicular parameters for the assessment of male fertility is necessary. Therefore, the present study aims to understand the effects of doxycycline on testicular germ cells of Wistar rats exposed to the drug doxycycline.

## **2. Material and Methods**

### **Animals**

Male adult Wistar rats (n=15, 320g, 100 days of life) were used. The animals were kept in polypropylene cages in 12-hour light/dark cycles at controlled room temperature (22°C), and free access to water and commercial food.

The animals were randomly divided into three experimental groups (n=5). All received 1 mL of solution (filtered water or treatment) administered orally, by gavage, for 30 days. Control group animals received water, while treated animals received doxycycline hyclate at doses of 10 and 30mg/kg/day. All procedures were approved by the Ethics Committee on the Use of Animals at the Federal University of Viçosa (CEUA/UFV, protocol 72/2017).

### **Biological samples**

The animals were weighed and received intraperitoneal anesthesia with a mixture of ketamine (100 mg/kg) and xylazine (10 mg/kg) and euthanized by exsanguination. The testes were removed, weighed and subsequently immersed and fixed in Karnovsky's solution (2.5% glutaraldehyde: 2.5% paraformaldehyde, in 0.1mol/L sodium phosphate buffer pH 7.2), for 24 hours. The Gonadosomatic index (%) was calculated as follows (GSI):  $TW/BW*100$  (TW= testes weight, BW= body weight).

After fixation, the testes were dehydrated in ethanol, and embedded in glycolmethacrylate (Histo-resin, Leica). Semi-thin sections (2µm thick) were stained with toluidine blue/1% sodium borate. Digital images were used for the morphological, morphometrical, and stereological analyses. For cell viability analysis, the same histological sections were used.

## Morphometry and stereology

### *Seminiferous tubules morphometry*

The mean tubular diameter of each animal was measured in 10 seminiferous tubules cross-sections. The same images were used to calculate the height of the seminiferous epithelium, which represented the average of two diametrically opposite measurements, starting from the basement membrane to the tubular lumen. All measurements were made using the Image-Pro Plus image analysis software from digital images of the seminiferous tubules at 200x magnification. From the tubular diameter and the height of the epithelium, it was possible to measure the tubular area (total area, area of the seminiferous epithelium and area of the lumen), using the following ratios:

- Lumen diameter = tubular diameter - (height of seminiferous epithelium x 2)
- Tubular radius (Rt) = tubular diameter/2;
- Lumen radius (Rlu)= lumen diameter/2;
- Seminiferous tubule area= $\pi R_t^2$
- Lumen area=  $\pi R_{lu}^2$
- Epithelial Area=Tubule Area - Lumen Area

The epithelium/tubule ratio (ETR) was calculated using the formula:

- ETR = Epithelial Area / Tubule Area

The volumetric proportions and volumes of testicular components were obtained by using a 120-point reticle (intersections) placed on the analyzed images, using the Image-Pro Plus image analysis software. The proportions were estimated by counting 3000 intersections projected onto random fields of the images, captured at 200x magnification. The proportions of seminiferous tubules, interstitium and Leydig cells were estimated. The volumes of testicular components were defined based on the proportion occupied by them given of the total net volume of the testicular parenchyma. According to França (1998), as the testicle density varies around 1 (1.03 to 1.04), the testicular weight was considered equal to its volume. Thus, the total net volume of the testicular parenchyma was defined by subtracting the weight of the tunica albuginea from the gross weight of the testis.

Based on the volumetric proportions, it was possible to quantify the somatic indexes, as described below (Dias et al. 2019):

- Parenchymasomatic Index = parenchyma weight/body weight x 100
- Tubulesomatic index = tubule weight/body weight x 100
- Epitheliumsomatic index = epithelial weight/body weight x100
- Length of seminiferous tubule = seminiferous tubule volume/ $\pi.R_t^2$

### *Germ cells count*

For the germ cells count, 15 seminiferous tubules cross-sections in stage VII/VIII of the seminiferous epithelium cycle were considered (Oakberg 1956). The count was performed by identifying the cellular nuclei of germ cells and Sertoli cell nucleoli, considering: type A spermatogonia (GoA); spermatocytes in preleptotene-leptotene (SPTL) and in pachytene (SPTP); rounded spermatids (RSPD), and Sertoli cells. The obtained counts were corrected using the formula (Amann and Almquist 1962):

$$\text{corrected n} = \text{count obtained} \times \frac{\text{cutting thickness}}{\text{cutting thickness} + \sqrt{\left(\frac{ND}{2}\right)^2 - \left(\frac{ND}{4}\right)^2}}$$

The mean nuclear diameter (ND) was obtained from the average of 10 nuclear (germ cells) or nucleolar (Sertoli cells) diameters at 400x magnification. Nuclear/nucleolar diameters were measured from digital images using Image-Pro Plus image analysis software.

The ratios between the germ cell numbers were calculated to assess the efficiency of the spermatogenic process and of the Sertoli cells, as follows:

- Primary spermatocytes in preleptotene-leptotene/type A spermatogonia, obtaining the efficiency coefficient of spermatogonial mitosis;
- Rounded spermatids/type A spermatogonia, obtaining the general yield of spermatogenesis;
- Rounded spermatids/primary spermatocytes in pachytene, obtaining the meiotic index;
- Rounded spermatids/nucleoli of Sertoli cells, obtaining the Sertoli cell index that measures the efficiency of this cell;
- Corrected total number of germ cells/Sertoli cell nucleoli, obtaining the total support capacity of the Sertoli cell.

### **Germ cell viability**

In order to assess the proportion of viable cells and/or cells undergoing death in the testicular parenchyma, the differential fluorescence staining method was used, applying propidium iodide (PI) and acridine orange (AO) (Mcgahon et al. 1995).

AO is a fluorescent compound that intercalates with viable cell DNA emitting uniform green fluorescence, while propidium iodide is a highly water-soluble fluorescent compound that is impermeable to intact cell membranes. Similar to AO, PI intercalates with cellular DNA, however it emits red fluorescence in dying cells. These cell markings are based on condensation and membrane integrity (Cury-Boaventura et al. 2006).

Histological sections (1µm-thick) were incubated for one minute in 1% acetic acid solution, followed by three baths (3 min each) in sodium phosphate-buffered saline (PBS, pH 6.0). Then, the slides were stained with 0.02% acridine orange, and propidium iodide, thus washed 3 times (3 min each) in PBS (pH 6.0). In the next step, the histological slides were immersed in a calcium chloride solution for 45 seconds, followed by three baths (3 min each) in PBS (pH 6.0). The finished slides were mounted with glycerin. Digital images were taken in an EVOS fl fluorescence microscope (Life Technologies, Carlsbad, Canada) at 505 nm (GFP: green filter) and 580nm (RFP: red filter).

Color distribution was considered as a discriminatory parameter. After defining the color range, the area containing viable cells (green), cells in the process of initial damage (yellow/orange) and dead cells (red) were quantified. Images were analyzed using Image Pro Plus software.

### **Statistics**

Data were tested for normality according to numerical parameters (skewness, coefficient of variation, mean, median and kurtosis), graphs (histograms and Q-Q plot), followed by the Shapiro-Wilk normality test. For data with normal distribution, the one-way ANOVA test was used, followed by Tukey's post-test, while for data with non-parametrical distribution, the Kruskal-Wallis test was used, followed by Dunn's post-test. All data were analyzed using Prisma software (version 8.0.1; GraphPad Software Inc., SanDieg, CA). The significance level was 0.05.

## **3. Results**

### **Body and testis biometry**

Body weight, testis weight, tunica albuginea weight, and testicular parenchyma weight, additionally the GSI and IPS did not change after the experimental protocol (Table 1).

## Testicular morphometry and stereology

The volumetric proportion of seminiferous tubule, seminiferous epithelium and tunica albuginea were not altered by doxycycline hyclate. The calculated epithelial and tubulesomatic indexes did not show any significant changes (Table 2).

**Table 1.** Biometric data of Wistar rats after treatment with Doxycycline hyclate for 30 days.

Parameters	Control	Dox 10mg/kg	Dox 30mg/kg
Body weight (g)	348.75±30.95	345.00±10.70	318.50±13.07
Testicular weight (g)	1.64±0.43	1.80±0.28	1.92±0.11
GSI (%)	0.48±0.16	0.52±0.08	0.60±0.05
Testicular parenchyma (g)	1.62±0.43	1.79±0.28	1.91±0.11
Tunica albuginea (g)	0.014±0.005	0.009±0.002	0.010±0.005
PSI (%)	0.47±0.16	0.52±0.08	0.61 ±0.06

GSI= Gonadosomatic index, PSI= parenchyma somatic index. Means with equal letters do not differ significantly from each other by the Tukey test ( $P>0.05$ ).

**Table 2.** Stereology of seminiferous tubules after treatment with Doxycycline hyclate for 30 days.

Parameters	Control	Dox 10mg/kg	Dox 30mg/kg
Tubule (%)	87.90±0.82	89.50±2.28	88.55±1.32
Epithelium (%)	79.57±0.77	81.68±1.97	82.33±1.40
Tunica albuginea (%)	0.42±0.50	0.0026±0.0006	0.0030±0.0017
Tubule (mL)	1.43±0.37	1.61±0.27	1.70±1.20
Epithelium (mL)	1.3±0.34	1.47±0.24	1.58±0.10
Tunica albuginea (mL)	0.0135±0.005	0.0093±0.002	0.0097±0.005
ESI (%)	0.33±0.10	0.38±0.06	0.44±0.05
TSI (%)	0.42±0.14	0.46±0.07	0.534±0.059

ESI= epithelium somatic index, TSI= tubule somatic index. Means with equal letters do not differ significantly from each other by the Tukey test ( $p>0.05$ ).

The diameter and the length of the seminiferous tubules, and the area of the seminiferous epithelium did not change after treatment, even though the diameter and area of the lumen were increased after the intake of doxycycline hyclate 30mg/kg/day. The seminiferous tubule length was not altered due to doxycycline intake (Table 3).

**Table 3.** Morphometry of the seminiferous tubules after the treatment with Doxycycline hyclate for 30 days.

Parameters	Control	Dox 10mg/kg	Dox 30mg/kg
TD ( $\mu\text{m}$ )	314.37±31.52 <sup>a</sup>	316.76±33.41 <sup>a</sup>	337.71±24.93 <sup>a</sup>
EH ( $\mu\text{m}$ )	106.87±8.77 <sup>a</sup>	101.80±13.80 <sup>a</sup>	105.65±11.03 <sup>a</sup>
LD ( $\mu\text{m}$ )	82.34±5.17 <sup>a</sup>	91.22±12.98 <sup>a</sup>	108.32±8.76 <sup>b</sup>
STL/t (m)	1.89×10 <sup>-5</sup> ±6.22×10 <sup>-6a</sup>	2.00×10 <sup>-5</sup> ±5.64×10 <sup>-6a</sup>	1.91×10 <sup>-5</sup> ±3.53×10 <sup>-5a</sup>
STL/gt (m)	1.14×10 <sup>-5</sup> ±2.47×10 <sup>-6a</sup>	2.71×10 <sup>-5</sup> ±3.43×10 <sup>-5a</sup>	9.89×10 <sup>-6</sup> ±1.51×10 <sup>-6a</sup>
ArT ( $\mu\text{m}^2$ )	78638.40±15318.62 <sup>a</sup>	83239.24±18540.21 <sup>a</sup>	90611.54±13537.7 <sup>a</sup>
ArE ( $\mu\text{m}^2$ )	72677.68±15614.17 <sup>a</sup>	60026.84±32264.31 <sup>a</sup>	80868.69±13212.23 <sup>a</sup>
ArL ( $\mu\text{m}^2$ )	5960.72±1118.44 <sup>a</sup>	7030.20±1927.39 <sup>a</sup>	9742.85±1318.04 <sup>b</sup>

TD= tubule diameter, EH= epithelium height, LD=Lumen diameter, STL/t= Length of the seminiferous tubule per testicle, STL/gt= Length of the seminiferous tubule per gram of testicle. ArT, ArL and ArE= areas of the seminiferous tubule, lumen and epithelium, respectively. Means with equal letters do not differ significantly from each other by the Tukey test ( $P>0.05$ ).

## Germ cells counts

The population of spermatogonia was reduced due to treatment with the highest dose of doxycycline, a result that may be associated with an increase in the area and diameter of the lumen in the same group (Table 4). The populations of spermatocytes, round spermatids and Sertoli cells were not altered.

Although the meiotic index was not altered, the mitotic index was found to be high in the group exposed to a dose of 30mg/kg/day of doxycycline (Table 4). The Sertoli cell index and the Sertoli cell

support capacity remained unchanged between experimental groups. Contrastingly, the overall spermatogenic yield was significantly higher after the ingestion of doxycycline hyclate at a dose of 30mg/kg/day (Table 4).

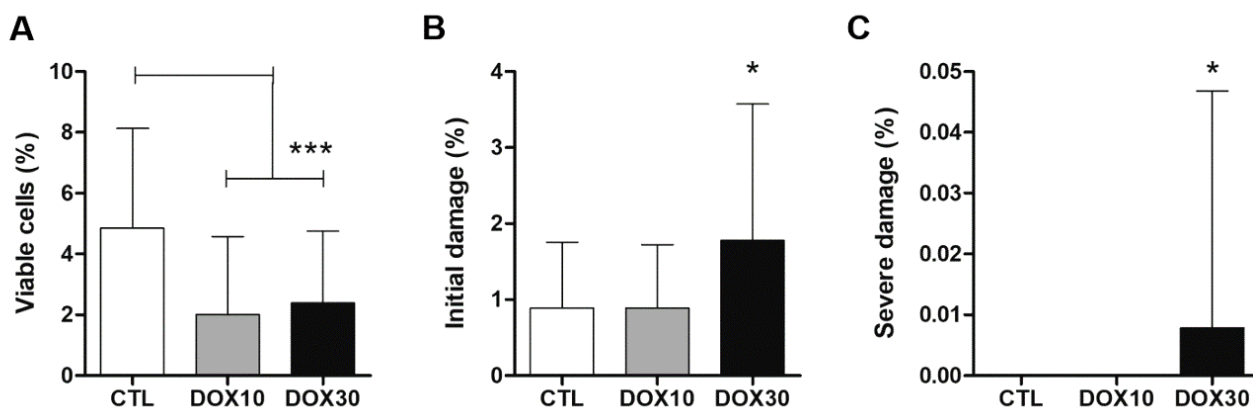
### Germ cell viability

The proportion of viable cells in the groups treated with doxycycline was lower ( $p < 0.001$ ) than that of the control group (Figure 1A). The decrease in the proportion of viable cells influenced a significant increase in cells undergoing a more severe damage process in the group treated with the highest dose of doxycycline (Figure 1B). The group that received the dose of 10mg/kg/day of doxycycline showed no important changes when compared to the control group. The administration of the highest dose of doxycycline (30mg/kg/day) caused a significant increase in the proportion of cells with severe damage (Figure 1C). The same behavior was not observed in the control groups and in the group treated with 10mg/kg/day of doxycycline.

**Table 4.** Germ cell count and testicular indexes by cross-section of seminiferous tubule at stage VII of the seminiferous epithelium cycle.

Parameters	Control	Dox 10mg/kg	Dox 30mg/kg
Spermatogonia	2.01±0.67 <sup>a</sup>	1.60±0.18 <sup>a</sup>	1.05±0.10 <sup>b</sup>
Preleptotene/Leptotene	19.96±4.58 <sup>a</sup>	25.17±2.55 <sup>a</sup>	23.73±3.27 <sup>a</sup>
Pachytene	25.12±2.15 <sup>a</sup>	28.26±5.36 <sup>a</sup>	25.49±2.37 <sup>a</sup>
Rounded spermatid	77.35±5.38 <sup>a</sup>	83.34±9.73 <sup>a</sup>	77.6±12.82 <sup>a</sup>
Sertoli Cell	4.43±0.97 <sup>a</sup>	3.72±0.34 <sup>a</sup>	3.62±0.67 <sup>a</sup>
Mitotic index	11.46±6.09 <sup>a</sup>	15.90±2.43 <sup>a</sup>	22.7±4.10 <sup>b</sup>
Meiotic index	3.08±0.19 <sup>a</sup>	2.99±0.41 <sup>a</sup>	3.04±0.20 <sup>a</sup>
Sertoli cell index	18.23±5.08 <sup>a</sup>	22.54±3.40 <sup>a</sup>	21.81±3.52 <sup>a</sup>
SCC	29.34±8.35 <sup>a</sup>	37.41±5.34 <sup>a</sup>	35.93±5.36 <sup>a</sup>
Spermatogenesis yield	42.74±16.88 <sup>a</sup>	52.53±7.68 <sup>a</sup>	74.13±11.32 <sup>b</sup>

SSC= Sertoli cell support capability. Means with equal letters do not differ significantly from each other by Tukey test ( $P > 0.05$ ).



**Figure 1.** Germ cell viability after doxycycline hyclate intake (10 and 30mg/mL). A - Germ cells that are viable (%); B - initial process of germ cells damage (%); C - severe germ cells damage (%). CTL= Control group; Dox 10= Doxycycline 10mg/mL; Dox 30= Doxycycline 30mg/mL. Results expressed with mean and standard deviation. \* = $p < 0.05$  and \*\*\*= $p < 0.01$ .

### 4. Discussion

Doxycycline is a broad-spectrum antibiotic of the tetracycline class used in the treatment of infections caused by bacteria and some parasites (Şekeroğlu et al. 2012). On account of its wide use, its of a great importance to evaluate its side effects, including in the male reproductive system. Although doxycycline does not cause changes in testicular biometrics and sperm yield, it causes a decrease in the number of spermatogonia.

The different doses of doxycycline did not interfere with the body and testicular weight, which corroborates the previous studies using doses of 7, 7.5, 14 and 28 mg/kg (Yeh et al. 2007; Elzeinová et al. 2013), suggesting a low systemic toxicity of the drug (Mouro et al. 2020). However, body mass should not be considered by itself as an important measure in the assessment of sperm parameters (Macdonald et al. 2013). Thus, testicular changes are mainly related to germ and somatic cells can occur even without changes in body or testicular weight.

Even though the testicular germ cell count showed a reduction in the number of spermatogonia in the group that received the highest dose of doxycycline, the evaluation of morphometric data did not show any significant change. On the other hand, Elzeinová et al. (2013) showed a reduction of the germinal epithelium thickness in animals treated with doxycycline, which may be associated with the loss of germ cells. Perhaps Elzeinová et al. (2013) found different results from this study because the treatment was done with immature animals where testicular cells are still developing and dividing at an accelerated pace being more susceptible to damage and injury.

The determination of cell division rates favors the understanding of the kinetics of the spermatogenic process. The evaluation of the mitotic index allowed us to quantify the generation of cell clones originated from spermatogonia, while the determination of the meiotic index helped us to observe the generation of haploid cells (Griswold et al. 2016; Fayomi et al. 2018). Preliminary *in vivo* studies indicate that doxycycline leads to a reduction in the mitotic index and the nuclear division index (Şekeroğlu et al. 2012). Nevertheless, *in vivo* studies showed increased mitotic indexes for the animals that received the highest dose of doxycycline, which may have led the Sertoli cell to adapt, increasing its support capacity, consequently leading to an overall spermatogenesis yield increase. Considering the complete duration of spermatogenesis in Wistar rats, which varies from 40 to 60 days (França et al. 1998), doxycycline may have been administered in the middle of the spermatogenic process, not being enough to affect cells committed to the meiotic process.

Apoptosis is a highly coordinated process induced by the activation of specific pathways and plays an important role in the removal of damaged cells. The activation of pathways that induce the death of damaged cells is dose-dependent, as well as the intensity of exposure to a cellular stressor (Franco et al. 2009). Although doxycycline is considered a drug of low toxicity (Sloan and Scheinfeld 2008), this study showed that the drug has a dose-dependent impact on cell viability. This impact on viability occurs because doxycycline shows an apoptotic action through the intrinsic pathway of mitochondria-dependent apoptosis (Sagar et al. 2010), but the exact mechanisms of this process are not yet known. Although a protective effect of doxycycline on testicular cells has been described (Sagar et al. 2010), the present study observed a reduction in the percentage of viable cells, possibly due to the higher dose administered.

## 5. Conclusions

The present study showed that exposure to doxycycline hyclate at a dose of 30mg/kg/day causes damage to the spermatogenic process, with a significant reduction in a primordial population of germ cells, the spermatogonia. Furthermore, there was a dose-dependent increase in the percentage of cells with damage, indicating that doxycycline can affect testicular germ cells, affecting the spermatogenic process in Wistar rats.

**Authors' Contributions:** LOPES-FERREIRA, JV, MACHADO, JC, DIAS, FCR, ALTOÉ, LS. Acquisition of data, analysis and data interpretation, drafting of manuscript. VILELA, RG, MATTA, SLP, GOMES, AO, GOMES, MLMG data analysis and statistics, data discussion, drafting the manuscript. GOMES, MLM concept and design. All authors have read and approved the final version of the manuscript.

**Conflicts of Interest:** The authors declare no conflicts of interest.

**Ethics Approval:** All procedures were approved by the Ethics Committee on the Use of Animals at the Universidade Federal de Viçosa (CEUA/UFV, protocol 72/2017).

**Acknowledgments:** The authors wish to thank Fundação de Amparo à Pesquisa do Estado de Minas Gerais for the financial support (FAPEMIG, grant number: APQ-02736-18 to MLMG).

## References

- AMANN, R.P. and ALMQUIST, J.O. Reproductive capacity of dairy bulls. VIII. Direct and indirect measurement of testicular sperm production. *Journal of Dairy Science*. 1962, **45**(6), 774-781. [https://doi.org/10.3168/jds.S0022-0302\(62\)89487-9](https://doi.org/10.3168/jds.S0022-0302(62)89487-9)
- CHOPRA, I. and ROBERTS, M. Tetracycline antibiotics: mode of action, applications, molecular biology, and epidemiology of bacterial resistance. *Microbiology and Molecular Biology reviews*. 2001, **65**(2), 232-260. <https://doi.org/10.1128/MMBR.65.2.232-260.2001>
- CORTEZ-MAYA, S., et al. Old antiprotozoal drugs: Are they still viable options for parasitic infections or new options for other diseases? *Current Medicinal Chemistry*. 2020, **27**(32), 5403-5428. <https://doi.org/10.2174/0929867326666190628163633>
- CURY-BONAVENTURA, M.F. et al. Comparative toxicity of oleic and linoleic acid on human lymphocytes. *Life Sciences*. 2006, **78**(13), 1448-1456. <https://doi.org/10.1016/j.lfs.2005.07.038>
- DIAS, F.C.R., et al. Hydroalcoholic extract of *Pfaffia glomerata* alters the organization of the seminiferous tubules by modulating the oxidative state and the microstructural reorganization of the mice testes. *Journal of Ethnopharmacology*. 2019, **233**, 179-189. <https://doi.org/10.1016/j.jep.2018.12.047>
- ELZEINOVÁ, F. et al. Adverse effect of tetracycline and doxycycline on testicular tissue and sperm parameters in CD1 outbred mice. *Experimental and Toxicology Pathology*. 2013, **65**(6), 911-917. <https://doi.org/10.1016/j.etp.2013.01.004>
- ERICSSON, R. J.; BAKER, V. F. Binding of tetracycline to mammalian spermatozoa. *Nature*. 1967, **214**(5086), 403-404. <https://doi.org/10.1038/214403a0>
- FAROMBI, E.O. et al. Tetracycline-induced reproductive toxicity in male rats: effects of vitamin C and N-acetylcysteine. *Experimental and Toxicology Pathology*. 2008, **60**(1), 77-85. <https://doi.org/10.1016/j.etp.2008.02.002>
- FAYOMI, A. P.; ORWIG, K. E. Spermatogonial stem cells and spermatogenesis in mice, monkeys and men. *Stem cell Research*. 2018, **29**, 207-214. <https://doi.org/10.1016/j.scr.2018.04.009>
- FRANCO, R et al. Environmental toxicity, oxidative stress and apoptosis: menage a trois. *Mutation Research/Genetic Toxicology and Environmental Mutagenesis*. 2009, **674**(1-2), 3-22. <https://doi.org/10.1016/j.mrgentox.2008.11.012>
- FRANÇA LR, R. L. The testis of domestic mammals. Male reproduction-a multidisciplinary overview. *Madrid: Churchill Comuncions Europe España*, **16**, 1998, 198-219.
- GRISWOLD, Michael D. Spermatogenesis: the commitment to meiosis. *Physiological reviews*. 2016, **96**(1), 1-17. <https://doi.org/10.1152/physrev.00013.2015>
- HARGREAVES, C.A. et al. Effects of co-trimoxazole, erythromycin, amoxycillin, tetracycline and chloroquine on sperm function in vitro. *Human Reproduction*. 1998, **13**(7), 1878-1886. <https://doi.org/10.1093/humrep/13.7.1878>
- HOLMES, Natasha E.; CHARLES, Patrick GP. Safety and efficacy review of doxycycline. *Clinical Medicine. Therapeutics*. 2009, **1**, 471-482. <https://doi.org/10.4137/CMT.S2035>
- HOU, Xiang et al. Testosterone disruptor effect and gut microbiome perturbation in mice: early life exposure to doxycycline. *Chemosphere*. 2019, **222**, 722-731. <https://doi.org/10.1016/j.chemosphere.2019.01.101>
- LANDERS, T.F. et al. A review of antibiotic use in food animals: perspective, policy, and potential. *Public health reports*. 2012, **127**(1), 4-22. <https://doi.org/10.1177/003335491212700103>
- LE TURNIER, P.; EPELBOIN, L. Update on leptospirosis. *La Revue de médecine interne*. 2018, **40**(5), 306-312. <https://doi.org/10.1016/j.revmed.2018.12.003>
- MACDONALD, A. A.; STEWART, A. W.; FARQUHAR, C. M. Body mass index in relation to semen quality and reproductive hormones in New Zealand men: a cross-sectional study in fertility clinics. *Human reproduction*. 2013, **28**(12), 3178-3187. <https://doi.org/10.1093/humrep/det379>
- MCGAHON, A.J. et al. The end of the (cell) line: methods for the study of apoptosis in vitro. *Methods in Cell Biology*. 1995, **46**, 153-187. [https://doi.org/10.1016/s0091-679x\(08\)61929-9](https://doi.org/10.1016/s0091-679x(08)61929-9)
- MOURO, V.G.S. et al. *Euterpe oleracea* (Martius) oil reverses testicular alterations caused after cadmium administration. *Biological trace element research*. 2020, **197**(2), 555-570. <https://doi.org/10.1007/s12011-019-02004-x>
- NODARI, R. et al. Effects of combined drug treatments on Plasmodium falciparum: In vitro assays with doxycycline, ivermectin and efflux pump inhibitors. *PLoS One*. 2020, **5**(4), e0232171. <https://doi.org/10.1371/journal.pone.0232171>
- OAKBERG, E.F. Duration of spermatogenesis in the mouse and timing of stages of the cycle of the seminiferous epithelium. *American Journal of Anatomy*. 1956, **99**(3), 507-516. <https://doi.org/10.1002/aja.1000990307>



SAGAR, S. S., BUSCH, B. K., and JOWETT, S. Success and failure, fear of failure, and coping responses of adolescent academy football players. *Journal of Applied Sport Psychology*. 2010, **22**(2), 213-230. <https://doi.org/10.1080/10413201003664962>

ŞEKEROĞLU, Z. A., AFAN, F., & ŞEKEROĞLU, V. Genotoxic and cytotoxic effects of doxycycline in cultured human peripheral blood lymphocytes. *Drug and Chemical Toxicology*. 2012, **35**(3), 334-340. <https://doi.org/10.3109/01480545.2011.621954>

SLOAN, B.; SCHEINFELD, N. The use and safety of doxycycline hyclate and other second-generation tetracyclines. *Expert Opinion on Drug Safety*. 2008, **7**(5), 571-577. <https://doi.org/10.1517/14740338.7.5.571>

YEH, Y.C et al. Protection by doxycycline against doxorubicin-induced oxidative stress and apoptosis in mouse testes. *Biochemical Pharmacology*. 2007, **74**(7), 969-980. <https://doi.org/10.1016/j.bcp.2007.06.031>

ZAENGLEIN, A. L. et al. Guidelines of care for the management of acne vulgaris. *Journal of the American Academy of Dermatology*. 2016, **74**(5), 945-973. <https://doi.org/10.1016/j.jaad.2015.12.037>

**Received:** 28 January 2022 | **Accepted:** 1 May 2022 | **Published:** 10 March 2023



This is an Open Access article distributed under the terms of the Creative Commons Attribution License, which permits unrestricted use, distribution, and reproduction in any medium, provided the original work is properly cited.