

## ASSESSMENT OF CARVACROL PASTE AS ENDODONTIC MEDICATION ASSOCIATED WITH LASER PHOTOBIO-MODULATION IN TISSUE REPAIR: AN EXPERIMENTAL STUDY IN RATS

### *AVALIAÇÃO DA PASTA DE CARVACROL COMO MEDICAÇÃO ENDODÔNTICA ASSOCIADA À FOTOBIO-MODULAÇÃO A LASER NO REPARO TECIDUAL: UM ESTUDO EXPERIMENTAL EM RATOS*

**Ismário Silva MENESES<sup>1</sup>; Ricardo Luiz Cavalcanti de ALBUQUERQUE JÚNIOR<sup>2</sup>; Felipe de Souza MATOS<sup>3</sup>; Aline Aragão Pereira MACEDO<sup>4</sup>; Adriano Antunes de Souza ARAÚJO<sup>5</sup>; Talita Dionízio SANTOS<sup>6</sup>; Nayara Santos SOUZA<sup>7</sup>; Luiz Renato PARANHOS<sup>8</sup>; Lucindo José QUINTANS-JÚNIOR<sup>9</sup>; Maria Amália Gonzaga RIBEIRO<sup>10</sup>**

1. DDS, MSc, Postgraduate Program in Dentistry, Federal University of Sergipe, Aracaju, SE, Brazil; 2. DDS, MSc, PhD, Department of Dentistry, Tiradentes University, Aracaju, SE, Brazil; 3. DDS, MSc, PhD, Postdoctoral Research Fellow, Postgraduate Program in Dentistry, School of Dentistry, Federal University of Uberlândia, Uberlândia, MG, Brazil. felipe\_smatos@hotmail.com; 4. DDS, MSc, Postgraduate Program in Dentistry, Federal University of Sergipe, Aracaju, SE, Brazil; 5. BSPS, MSc, PhD, Department of Pharmacy, Federal University of Sergipe, São Cristóvão, SE, Brazil; 6. DDS, MSc, Postgraduate Program in Dentistry, Federal University of Sergipe, Aracaju, SE, Brazil; 7. DDS, Department of Dentistry, Federal University of Sergipe, Aracaju, SE, Brazil; 8. DDS, MSc, PhD, Department of Preventive and Social Dentistry, School of Dentistry, Federal University of Uberlândia, Uberlândia, MG, Brazil; 9. BSPS, MSc, PhD, Department of Physiology, Federal University of Sergipe, São Cristóvão, SE, Brazil; 10. DDS, MSc, PhD, Department of Dentistry, Federal University of Sergipe, Aracaju, SE, Brazil.

**ABSTRACT:** This study aimed to analyze the tissue reaction caused by carvacrol paste associated or not with laser photobiomodulation (LPBM) at  $\lambda 660$  nm in the subcutaneous tissue of rats. Sixty Wistar rats were divided into four groups and they received the following interventions: subcutaneous implantation of empty polyethylene tubes (CTR), implantation of tubes containing carvacrol paste (CVC), implantation of empty tubes and LPBM (LLLT), and implantation of tubes containing carvacrol paste and LPBM (CVCLT). The animals were euthanized at three, eight, and 15 days after surgery. The inflammatory reaction and fibroplasia were analyzed histomorphometrically. Significant differences among the groups were determined by ANOVA and Tukey's test ( $p < 0.05$ ). In the 3-day period, the CVCLT group had low inflammatory infiltration ( $p < 0.01$ ). In the 8- and 15-day periods, the LLLT and CVCLT groups presented a low amount of lymphocytic inflammatory infiltrate ( $p < 0.01$  and  $p < 0.05$ ). Regarding the formation of fibrous tissue, the CVC group had the highest formation of type III collagen in the 8-day period ( $p < 0.001$ ). In the 15-day period, the CVCLT group had a lower formation of type I collagen than the CTR and LLLT groups ( $p < 0.05$ ). The use of the carvacrol paste associated with photobiomodulation optimizes the inflammatory period and tissue repair.

**KEYWORDS:** Biocompatible materials. Carvacrol. Endodontics. Laser therapy. Wound healing.

## INTRODUCTION

One of the major problems in Endodontics is the increasing number of microorganisms highly resistant to conventional endodontic treatment due to the complexity of root canal systems. In this light, new natural herbal products have been added to the use of antiseptic irrigators and intracanal medications, as well as equipment which main premise is to create conditions to improve cellular metabolism, reducing postoperative pain and tissue repair time (DEVARAJ et al., 2016).

The inflammation process is characterized by the production of a cascade of mediators that regulate important factors of the inflammatory

response, such as vascular permeability and recruitment of defense cells, such as leukocytes (VELNAR et al., 2009). Once released, these inflammatory mediators may activate or sensitize the nociceptors adjacent to the tissue injured, resulting in the sensation of pain (ANDRADE et al., 2012).

The use of biomaterials in the cicatricial process has drawn the attention of the scientific community, aiming to modulate or accelerate the process of tissue repair (FARIAS et al., 2016; CHEN; LIU, 2016; CARVALHO et al., 2018). Natural biomaterials such as medicinal plant substrates are considered a significant source of new chemicals with potential therapeutic effects

(CALIXTO, 2005; IPEK et al., 2005). In endodontics, factors such as cytotoxicity and resistance of microorganisms tend to replace the use of standard medications with those prepared from natural plants (KARKARE et al., 2015; DHARIWAL et al., 2016; FARIAS et al., 2016; TONEA et al., 2017). Among them, carvacrol (5-isopropyl-2-methylphenol) - a monoterpene phenol present in the essential oils of numerous aromatic plants - has shown antimicrobial (KLEIN et al., 2013), antioxidant (BEENA et al., 2013), antinociceptive (MELO et al., 2012), and anti-inflammatory effects (LANDA et al., 2009).

Studies have shown that the topical application of carvacrol as a gel-based formulation reduced tissue lesion and prevented alveolar bone loss and the growth of periodontal microorganisms in a rat model of periodontitis (BOTELHO et al., 2008, 2009). Furthermore, carvacrol has also shown antimicrobial activity against *Candida albicans* (CHAMI et al., 2004) and *Enterococcus faecalis* (NOSRAT et al., 2009). The latter, in turn, has been frequently identified as one of the most common species in root canals with failed endodontic treatment (MA et al., 2011; WILSON et al., 2015).

Another resource that is well established and widely used to stimulate tissue repair is low-level laser therapy (LLLT), which has analgesic, anti-inflammatory, and anti-edematous action, aiding the process of tissue repair through photobiomodulation. The interaction of laser with biological tissues depends on wavelength, energy density, and power. Among the mechanisms involved in the biological effects of LLLT, there is an increase in local microcirculation, angiogenesis, vasodilation, and inhibition of inflammatory mediators such as prostaglandins (RIBEIRO et al., 2009; MATOS et al., 2014).

Previous studies have shown that the use of carvacrol in addition to its antimicrobial potential (CHAMI et al., 2004; BOTELHO et al., 2008, 2009; NOSRAT et al., 2009; KLEIN et al., 2013), decreases the inflammation time of the lesions thus accelerating tissue repair (LANDA et al., 2009; MELO et al., 2012; BEENA et al., 2013; KLEIN et al., 2013). The same benefits are also seen in the application of laser photobiomodulation (LPBM) (ROCHA-JUNIOR et al., 2006; OLIVEIRA et al., 2009; RIBEIRO et al., 2009; FIRIO et al., 2011; LARAIA et al., 2012; MATOS et al., 2014, 2018). These properties highlight carvacrol as a promising agent to treat infectious diseases such as endodontic infections, and it could be a safe and effective alternative of endodontic medication. However, the effects of the topical application of carvacrol

associated or not with LPBM on tissue reaction have not been studied yet. Thus, this study aimed to evaluate the tissue reaction caused by carvacrol paste associated or not with LPBM at  $\lambda 660$  nm in the subcutaneous tissue of rats.

## MATERIAL AND METHODS

### Sample and division of groups

The local Institute Review Board approved the research protocol (Process n. 59/2011). Sixty male *Rattus norvegicus* (Wistar lineage), aged 120-150 days, and weighing 250-300 g were used. The sample size was calculated based on the data from a previous study using the same experimental design (MATOS et al., 2014) and a quantitative analysis of mast cells. For the calculation, the options used were power calculation, continuous outcome, and superiority trial, on the Sealed Envelope website. Three specimens per group were required considering  $\alpha$  at 0.05, power at 95%, mean outcome in the control group of 28.7 (MATOS et al., 2014), mean outcome in the experimental group of 20 (MATOS et al., 2014), and standard deviation of the outcome of 2.5 (MATOS et al., 2014). Therefore, the final study sample of 60 animals is suitable and meets the requirements. The animals were randomly assigned to four groups ( $n = 15$ ) according to the following interventions: subcutaneous implantation of empty polyethylene tubes (CTR), implantation of tubes containing carvacrol paste (CVC), implantation of empty tubes and laser photobiomodulation (LLLT), and implantation of tubes containing carvacrol paste and laser photobiomodulation (CVCLT).

### Preparation of polyethylene tubes and carvacrol paste

To simulate the root canal space and insert the carvacrol paste, polyethylene tubes were prepared following the methodology described by Torneck et al. (1966) and Matos et al. (2014), using an urethral catheter of 1.5 mm of internal diameter (VANHOLDER et al., 1993; MATOS et al., 2014). Each tube was sealed at one end with Cyanoacrylate Ester gel (Super Bonder, Aachen, Germany) to prevent the excessive overflow of the materials (MATOS et al., 2014). Carvacrol was obtained commercially from Sigma-Aldrich (USA) at 98% purity. The carvacrol paste was prepared with the following components and proportions: 0.26 g of carvacrol, 2 g of beta-cyclodextrin, and 2 ml of distilled water (GUIMARÃES et al., 2012; LIMA et al., 2013). After preparing the paste, the sterilized polyethylene tubes were filled immediately with the

aid of a sterile needle compatible with the internal diameter of the tubes.

### Implantation of polyethylene tubes

The polyethylene tubes containing carvacrol paste were implanted following the technique previously described by our team, after intraperitoneal anesthesia, trichotomy, and antisepsis (MATOS et al., 2014). In the CVC and CVCLT groups, which tubes were completely filled with the carvacrol paste, the sealed end of the tube was implanted facing the caudal region. All animals received an intramuscular dose of diclofenac potassium (10 mg/kg) and an intraperitoneal dose of 10% enrofloxacin (50 mg/kg) to minimize postoperative symptomatology.

### Laser photobiomodulation

After the surgical procedures, the animals of the LLLT and CVCLT groups were submitted to laser light exposure using a calibrated Twin Laser-InGaAlP apparatus (MMOPTICS, São Carlos, SP, Brazil) at  $\lambda 660$  nm, following the protocol described by Ribeiro et al. (2009): continuous emission mode (CW), 10 mW output power, 1 mW/cm<sup>2</sup> power density, 0.8 J total energy per point, and 20 J/cm<sup>2</sup> energy density. Irradiation was applied perpendicularly and by contact, perpendicular to the long axis of the back of the animal, in four points of each wound: one caudal, one radial, and two lateral (right and left), with an exposure time of 20 s per point. The irradiations occurred at intervals of 48 hours, and the first application was immediately after the surgical procedure (RIBEIRO et al., 2009; MATOS et al., 2014). The non-irradiated animals were submitted to the laser emitter off, simulating the same conditions of manipulation and stress.

### Euthanasia and sample preparation

Three, eight, and 15 days after the surgical procedures, the animals were euthanized and the specimens were removed from each animal and processed histologically (MATOS et al., 2014) for hematoxylin-eosin (HE) and sirius red (SR) staining.

### Evaluation of inflammatory infiltrate intensity

The histomorphological characteristics associated with the cicatricial evolution were evaluated from histological sections stained with HE in eight serial sections of each animal, based on the methodology by Scott et al. (1991). Stromal elements were analyzed semi-quantitatively, observing the inflammatory aspects through polymorphonuclear neutrophils.

### Evaluation of collagen deposition

Collagen fibers were analyzed according to their red or orange birefringence pattern for type I collagen and green or yellow-green for type III collagen (ALBUQUERQUE-JÚNIOR et al., 2009). The morphological appearance (wavy or stretched, thin or thick, short or long) and the architectural arrangement (reticular, parallel, or interlaced) were also evaluated. Density was assessed as to the condition of interfibrillar spaces or collagenized tissue.

The images of collagen areas were obtained and evaluated with the Image J software (NIH, USA), using the Threshold Color plugin to obtain the percentage of collagen by means of automated particle analysis according to the standard established for collagen type I (0-35 shade for red color) and type III (45-120 shade for green color). The values of saturation (0-255) and brightness (5-225) were standardized for all images. After quantifying type I and type III collagen areas based on the color in each field, the mean for each wound was calculated and recorded.

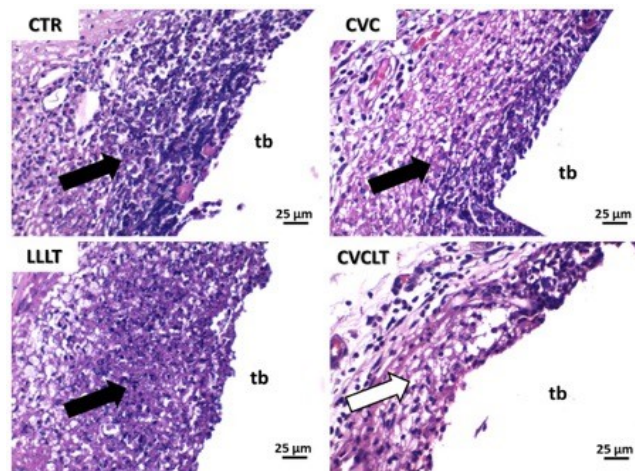
### Data analysis

The data were submitted to Shapiro-Wilk and Bartlett tests for analysis of normality and homoscedasticity, confirming the distribution symmetry, as well as additivity and constant variance of the results. Analysis of variance (ANOVA) was applied for the analysis of significant differences between the means of the different groups, and Tukey's post-hoc test was applied for multiple comparisons of the means, matching the groups two to two. The significance level used in this study was 5% ( $p < 0.05$ ).

## RESULTS

### Evaluation of inflammatory infiltrate intensity

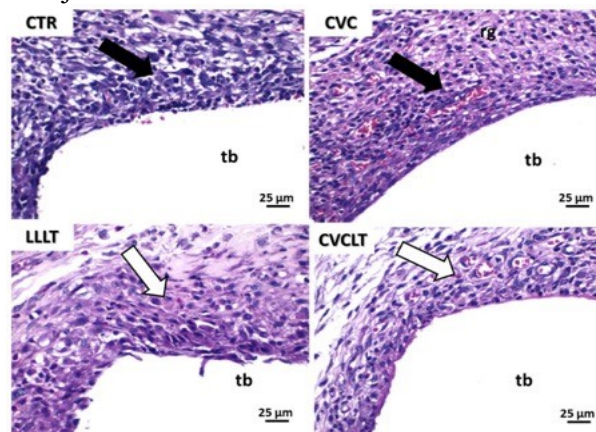
In three days, all groups showed a predominance of acute inflammatory reaction, rich in polymorphonuclear neutrophils, which focused on the regions closely related to the open end of the polyethylene tubes. In these areas, the formation of extensive deposits of serofibrinous exudate was also common. In the periphery and around the tubular end, chronic inflammatory infiltrate and interstitial edema ranging from mild to moderate were observed. As observed in Figure 1, the presence of carvacrol determined a significantly greater accumulation of polymorphonuclear neutrophils in the CVC group when compared to the other groups.



**Figure 1.** Photomicrographs of histological sections stained with HE of the different experimental groups representing the third day of implantation of the polyethylene tubes (tb). Polymorphonuclear neutrophils and serofibrinous exudate tend to accumulate in the circumferences of the open end of the tubes (black arrow). Moderate chronic inflammation and peripheral interstitial edema are observed, with a higher vasculo-capillary condensation in CVCLT (white arrow) as opposed to a greater range of neutrophil infiltration than the other groups. CTR (empty tubes), CVC (tubes containing carvacrol), LLLT (empty tubes irradiated with laser light), and CVCLT (tubes containing carvacrol and irradiated with laser light).

In eight days (Figure 2), the CTR group presented only mild to moderate peritubular fibroblast reaction, with the presence of discrete chronic inflammatory infiltrate and remnant interstitial edema. The laser irradiation on the area of implantation of the empty polypropylene tube (LLLT) determined the formation of a more expressive fibroblastic reaction and absence of interstitial edema. In the region adjacent to the tube

containing carvacrol (CVC), an exuberant granulation reaction was observed, with persistence of inflammatory lymphohistiocytic infiltrate. In contrast, the connective tissue surrounding the area containing tubes filled with carvacrol and subjected to irradiation exhibited a thick range of peritubular granulation reaction, rich in hyperemic capillary vessels and spindle cells interpreted as fibroblasts.

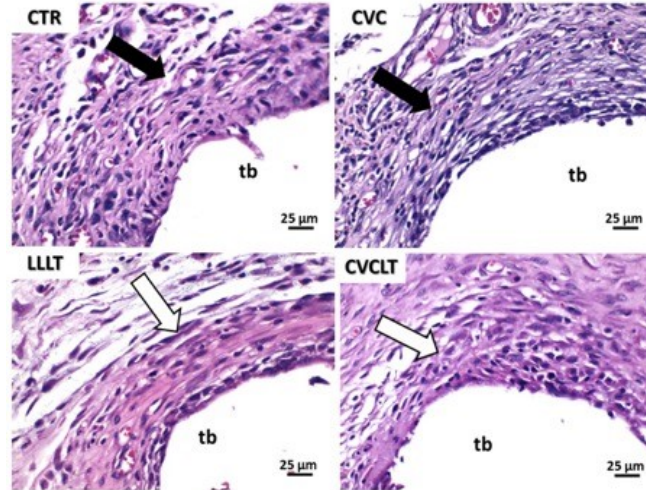


**Figure 2.** Photomicrographs of histological sections stained with HE of the different experimental groups representing the eighth day of implantation of the polyethylene tubes (tb). Persistent polymorphonuclear neutrophils and serofibrinous exudate in the CTR and CVC groups, which also show a persistent peritubular fibroblast reaction (black arrow) and persistent interstitial edema, while LLLT and CVCLT present an intense peritubular fibroblast reaction (white arrow), the latter also shows the persistence of richly vascular exuberant granulation reaction. CTR (empty tubes), CVC (tubes containing carvacrol), LLLT (empty tubes irradiated with laser light), and CVCLT (tubes containing carvacrol and irradiated with laser light).

In 15 days (Figure 3), the CTR and CVC groups showed fibroblasts and mild to moderate peritubular reaction, with an inexpressive presence of chronic inflammatory infiltrate and remnant

interstitial edema. In the irradiated groups (LLL and CVCLT), there is an abundant presence of collagens, especially in the peritubular spaces on the

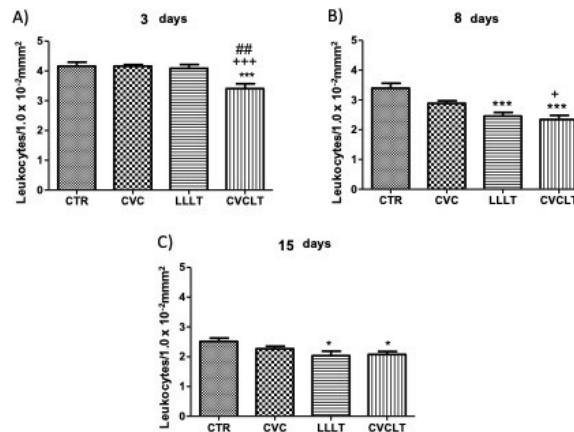
area of implantation of the empty polypropylene tube.



**Figure 3.** Photomicrographs of histological sections stained with HE of the different experimental groups representing the fifteenth day of implantation of the polyethylene tubes (tb). Presence of fibroblasts in the CTR and CVC groups, which also show a discrete peritubular fibroblastic reaction (black arrow), while LLLT and CVCLT present collagen in the peritubular spaces (white arrow). CTR (empty tubes), CVC (tubes containing carvacrol), LLLT (empty tubes irradiated with laser light), and CVCLT (tubes containing carvacrol and irradiated with laser light).

Regarding the quantitative analysis of the inflammatory process, carvacrol associated with LPBM (CVCLT) showed lower inflammatory infiltration than the CTR, CVC, and LLLT ( $p < 0.01$ ) groups within three days. In the 8-day period, the LLLT and CVCLT groups had a lower amount of

lymphocytic inflammatory infiltrate than the CTR and CVC ( $p < 0.05$ ) groups. In the 15-day evaluation period, LLLT and CVCLT presented a lower amount of lymphocytic inflammatory infiltrate in relation to the other groups ( $p < 0.05$ ) (Figure 1,2,3,4).



**Figure 4.** Distribution of the inflammatory process (leukocytes) by area of evaluation of all experimental groups throughout the three evaluation periods. A) The CVCLT group had a lower amount of leukocytes compared to the CTR and CVC groups ( $*** p < 0.001$ ). It also presented statistical difference when compared to the LLLT group ( $** p < 0.01$ ). B) The LLLT and CVCLT groups had less leukocytes compared to the other groups and they were statistically different in relation to the CTR group ( $*** p < 0.001$ ). The CVCLT group also presented a difference compared to the CVC group ( $p < 0.05$ ). There was no statistical difference between LLLT and CVC. C) The LLLT and CVCLT groups had a lower amount of leukocytes than the CTR group ( $p < 0.05$ ). No statistical differences were observed between CVC, LLLT, and CVCLT. CTR (control), CVC (carvacrol), LLLT (laser photobiomodulation), and CVCLT (carvacrol + laser photobiomodulation). (One-way ANOVA followed by Tukey's test).

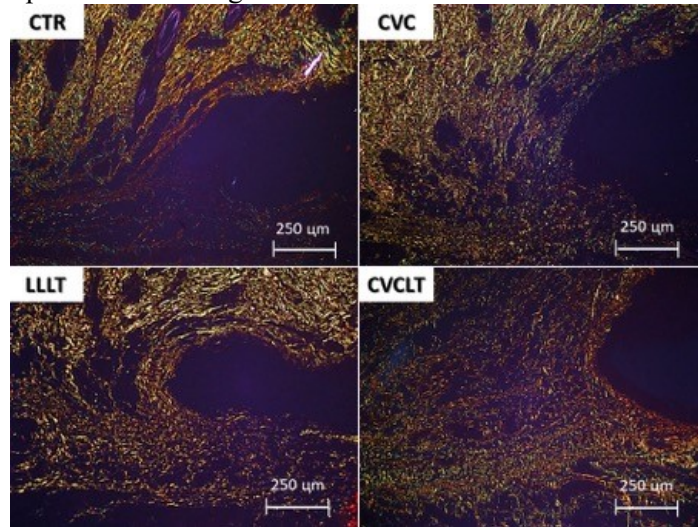
**Evaluation of collagen deposition**

At three days, the sections stained with SR and examined under polarized light revealed in all

groups the presence of rare fibrous bundles predominantly short, thin, and delicate, with greenish birefringence suggestive of type III

collagen throughout the wounded region. These fibrils appeared to be arranged in reticular organization, recalling a "spider web" arrangement.

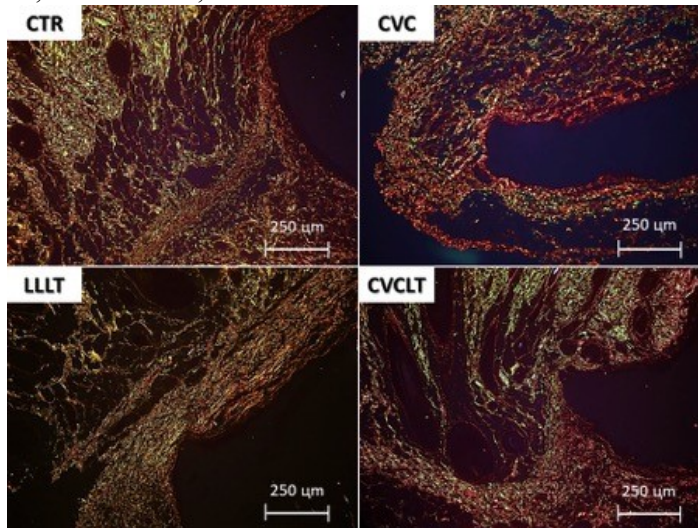
Interfibrillar spaces were abundant, large, and irregular (Figure 5).



**Figure 5.** Photomicrographs of histological sections stained with sirius red of the different experimental groups representing the third day of implantation of the polyethylene tubes (tb). All groups showed predominance of type III collagen. Thin and delicate fibrils of collagen with short and wavy appearance. Both groups treated with LLLT exhibited higher density of collagen deposition, with clearly less apparent thick interfibrillar spaces.

In the eighth day (Figure 6), all groups presented collagen fibers with predominantly reddish orange and reddish birefringence compatible with type I collagen, which were arranged in a reticular architectural arrangement on the surface of the wounds, but they were significantly parallel in depth. In groups CTR, CVC, and CVCLT, the fibers

are densely arranged, interlaced, compacted, and with reduction of interfibrillar spaces, characterizing a greater density and maturity of collagenization. The LLLT group presented better pattern of organization and maturation of types I and III collagen fibers.



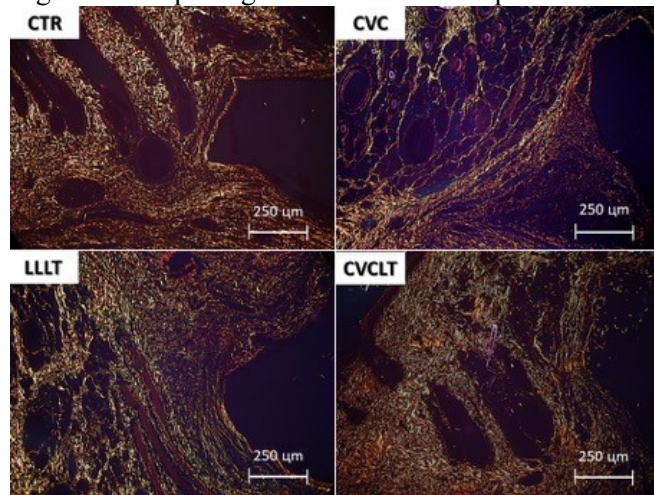
**Figure 6.** Photomicrographs of histological sections stained with sirius red of the different experimental groups representing the eighth day of implantation of the polyethylene tubes (tb). All groups showed a predominance of type I collagen. The CTR and CVC groups had thin, irregularly arranged fibers, and very apparent interfibrillar spaces. The LLLT and CVCLT groups present thicker and longer fibers, densely arranged (with little apparent interfibrillar spaces), and with a clear parallel arrangement.

In 15 days (Figure 7), the collagen mesh was composed of thicker and longer collagen fibers in the experimental groups (CVC, LLLT, and CVCLT). The fibers were organized in an

architectural arrangement clearly parallel to the end of the polyethylene tube, forming less conspicuous and morphologically irregular and narrowed interfibrillar spaces. Although the density of

collagenation was very similar between the groups, a thicker and more elongated morphological

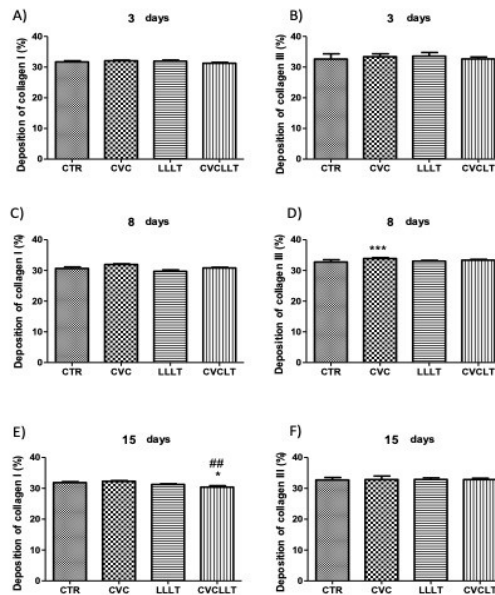
appearance of the fibers was observed in CVCLT when compared to the other groups.



**Figure 7.** Photomicrographs of histological sections stained with sirius red of the different experimental groups representing the fifteenth day of implantation of the polyethylene tubes (tb). It is still possible to observe large amounts of type I collagen fibers in all groups (CTR, CVC, LLLT, and CVCLT). However, it is also possible to observe the presence of type III collagen in the CVC, LLLT, and CVCLT groups, especially highlighted in the latter group.

Regarding the evaluation of types I and III collagen, it was observed, in the 3-day evaluation period, the presence of short, thin, and delicate fibers with green birefringence suggestive of type III collagen predominated in all groups (CTR, CVC, LLLT, and CVCLT), with no statistical difference between them. In the 8-day period, the only

difference observed was between the CVC and CTR groups (\*\**p*<0.001) and only for type III collagen. While in the 15-day period, the only significant difference observed was between the CVCLT and CTR groups and between CVCLT and LLLT in the evaluation of type I collagen (\* *p*<0.05) (Figures 5,6,7,8).



**Figure 8.** Mean percentage index of the type I and III collagen arrangement in the subcutaneous tissue repair of rats evaluated by sirius red (polarized light, 400x magnification) over the three (A and B), eight ( C and D), and 15 experimental days (E and F): CTR (control), CVC (carvacrol), LLLT (laser photobiomodulation), and CVCLT (carvacrol + laser photobiomodulation). Significant difference between the CVC and CTR groups in the 8-day evaluation of type III collagen (\*\**p*<0.001). # Significant difference between CVCLT and CTR and between CVCLT and LLLT in the evaluation of type I collagen in the 15-day period (\* *p*<0.05). (One-way ANOVA followed by Tukey's test).

## DISCUSSION

Despite the advances in endodontic therapy over recent decades, new disinfection strategies in the treatment of root canals should be planned for the elimination of persistent microorganisms. The research with natural biomaterials has increased due to the search for new substances with higher pharmacological activity, greater biocompatibility, lower toxicity, and low cost. The importance of better understanding the physical, chemical, and biological properties for a correct clinical indication of biomaterials has increasingly raised the interest in this subject. This study aimed to evaluate the tissue response caused by carvacrol paste associated or not with laser photobiomodulation (LPBM) at  $\lambda 660$  nm in the subcutaneous tissue of rats.

The anti-inflammatory and antibacterial properties of carvacrol make it a promising agent to treat endodontic lesions of infectious origin. Nosrat et al. (2009) has already shown the bactericidal effect of carvacrol as an irrigant on *E. faecalis* in root canal systems, concluding that it could destroy cell membranes and inhibit ATPase activity. Carvacrol has anti-inflammatory and antihyperalgesic properties because it reduces the threshold of neuronal excitability, inhibits the migration of neutrophils, and suppresses prostaglandin production, thus reducing inflammatory pain (WAGNER et al., 1986; IPEK et al., 2005; LANDA et al., 2009; GUIMARÃES et al., 2012; MELO et al., 2012; BEENA et al., 2013; LIMA et al., 2013). This study allowed verifying the significant reduction of neutrophil infiltrate in the groups that used carvacrol (CVC and CVCLT), especially in the periods of three and five days. Although the applicability of natural products in endodontics is confirmed, it is still difficult to standardize the methodological criteria either in study design or in the choice of product, concentrations, and pharmaceutical formulations.

The possibility of accelerating the healing and closure of cutaneous lesions using chemical or physical resources has been the object of numerous investigations (RIBEIRO et al., 2009; MATOS et al., 2014; ZIELINS et al., 2014; CHILDS; MURTHY, 2017). Laser therapy has been highlighted as an agent that accelerates the repair of cutaneous wounds by its biostimulatory effects. *In vivo* and *in vitro* studies have shown that laser treatment accelerates biochemical reactions, fibroblast activity, collagen metabolism, and neovascularization, and it promotes the activation of lymphocytes and analgesic and anti-inflammatory effects (ALBUQUERQUE-JÚNIOR et al., 2009;

RIBEIRO et al., 2009; MATOS et al., 2014; LORETI et al., 2015). These effects were observed in the two groups irradiated with laser light (LLLT and CVCLT) (POSTEN et al., 2005; SILVEIRA et al., 2011).

The results obtained in the present study from the analysis of the histological grading of the cicatricial repair (SCOTT, 1991) were the ones that established a better relationship between the different histological parameters and the progress of repair, allowing a better distinction between the phases analyzed. Some adaptations were made to the grading system, as previously recommended (ALBUQUERQUE-JÚNIOR et al., 2009), such as the removal of the eosinophils parameter and adjustment of correction factors for chronic inflammation to improve and facilitate data analysis and to establish a better difference between the phases of the repair.

As for the fibroblastic proliferation evaluated in the present study, a higher activity of these cells was verified at eight and 15 days in the LLLT and CVCLT groups compared to the CTR and CVC groups. These results showed the photobiomodulation effects of the laser in the proliferative phase of the repair, in agreement with other studies (ALBUQUERQUE-JUNIOR et al., 2009; LANDA et al., 2009; RIBEIRO et al., 2009; LARAIA et al., 2012; MELO et al., 2012; MATOS et al., 2014) that reported the greater interaction of the laser with cells damaged by trauma. In the irradiated groups at 15 days, a higher proliferative intensity was also observed compared to the CTR and CVC groups.

Collagen deposition showed a significant increase only in groups CVC (within eight days) and CTR and LLLT (within 15 days) when compared to the other groups at the three evaluation intervals. Studies using the sirius red staining technique, when analyzed by polarized light microscopy, observed collagen through birefringence, in which type I collagen is evident in yellow to red color, while type III collagen fibers are greenish, and the rest of the cells appear black (LIMA et al., 2013).

The collagen analysis in sirius red staining can measure not only the red areas corresponding to collagens type I and II but also the other areas in yellow and green, such as type III collagen (SILVEIRA et al., 2011). Thus, this technique was sensitive to changes in the present study, considering there were differences between the groups. There was no significant difference in the deposition and distribution of collagen fibers in the 3-day period, similar to the result by Albuquerque-Júnior et al. (2009).



Vascular neoformation at the beginning of the repair process is vital to carry oxygen and essential nutrients for tissue neoformation, with subsequent regression of these vessels in the remodeling stage (OLIVEIRA et al., 2009; RIBEIRO et al., 2009; FIRIO et al., 2011; LARAIA et al., 2012). Newly formed vessels are responsible for the recruitment of inflammatory cells that allow the continuous release of proinflammatory cytokines responsible for the prolongation of inflammation (ROCHA-JUNIOR et al., 2006; OLIVEIRA et al., 2009). In this study, neoformed vessels were found with greater evidence in the CVC and CVCLT groups (three and eight days) different from the other groups (CTR and LLLT), thus suggesting that carvacrol has angiogenesis ability as reported in other studies (LANDA et al., 2009; GUIMARÃES et al., 2012; MELO et al., 2012; BEENA et al., 2013; LIMA et al., 2013).

## CONCLUSION

Carvacrol paste alone or associated with laser photobiomodulation (LPBM) promotes biological events favoring the tissue repair of subcutaneous lesions on the dorsum of rats. It should be noted that the groups submitted to the combination of the two therapies (CVCLT) presented the best results, accelerating the repair process of the wounded area, observed through the decrease of the inflammatory phase and fibroblastic maturation, which suggests better tissue repair. Thus, the use of carvacrol paste as an intracanal medication associated or not with LPBM could improve the repair process of endodontic lesions. New studies evaluating its antimicrobial and healing potential should be considered.

---

**RESUMO:** Este estudo teve como objetivo analisar a reação tecidual causada pela pasta de carvacrol associada ou não à fotobiomodulação a laser (LPBM) a  $\lambda 660$  nm no tecido subcutâneo de ratos. Sessenta ratos Wistar foram divididos em quatro grupos e receberam as seguintes intervenções: implantação subcutânea de tubos de polietileno vazios (CTR); implantação de tubos contendo pasta de carvacrol (CVC); implantação de tubos vazios e LPBM (LLLT); implantação de tubos contendo pasta de carvacrol e LPBM (CVCLT). Os animais foram eutanasiados aos 03, 08 e 15 dias após a cirurgia. A reação inflamatória e a fibroplasia foram analisadas histologicamente. Diferenças significativas entre os grupos foram determinadas pelo teste ANOVA e teste de Tukey ( $p < 0,05$ ). No período de três dias, o grupo CVCLT apresentou menor infiltração inflamatória ( $p < 0,01$ ). No período de 8 e 15 dias, os grupos LLLT e CVCLT apresentaram menor quantidade de infiltrado inflamatório linfocitário ( $p < 0,01$  e  $p < 0,05$ ). Em relação à formação de tecido fibroso, o grupo CVC apresentou maior formação de colágeno tipo III no período de 8 dias ( $p < 0,001$ ). No período de 15 dias, o grupo CVCLT apresentou menor formação de colágeno tipo I em relação aos grupos CTR e LLLT ( $p < 0,05$ ). O uso da pasta de carvacrol associado à fotobiomodulação a laser otimiza o período inflamatório e o reparo tecidual.

**PALAVRAS-CHAVE:** Materiais biocompatíveis. Carvacrol. Endodontia. Terapia a laser. Cicatrização de feridas.

---

## REFERENCES

- ALBUQUERQUE-JÚNIOR, R. L. C. et al. Effect of bovine type-I collagen-based films containing red propolis on dermal wound healing in rodent model. *Int J Morphol*, v. 27, n. 4, p. 1105–1110, 2009. <https://doi.org/10.4067/S0717-95022009000400025>
- ANDRADE, E. L.; MEOTTI, F. C.; CALIXTO, J. B. TRPA1 antagonists as potential analgesic drugs. *Pharmacology and Therapeutics*, v. 133, n. 2, p. 189–204, 2012. <https://doi.org/10.1016/j.pharmthera.2011.10.008>
- BEENA; KUMAR, D.; RAWAT, D. S. Synthesis and antioxidant activity of thymol and carvacrol based schiff bases. *Bioorganic and Medicinal Chemistry Letters*, v. 23, n. 3, p. 641–645, 2013. <https://doi.org/10.1016/j.bmcl.2012.12.001>

- BOTELHO, M. A. et al. Effects of a herbal gel containing carvacrol and chalcones on alveolar bone resorption in rats on experimental periodontitis. **Phytother Res**, v. 22, n. 4, p. 442–449, 2008. <https://doi.org/10.1002/ptr.2325>
- BOTELHO, M. A. et al. Protective effect of locally applied carvacrol gel on ligature-induced periodontitis in rats: a tapping mode AFM study. **Phytother Res**, v. 23, n. 10, p. 1439–1448, 2009. <https://doi.org/10.1002/ptr.2798>
- CALIXTO, J. B. Twenty-five years of research on medicinal plants in Latin America: a personal view. **Journal of Ethnopharmacology**, v. 100, n. 1–2, p. 131–134, 2005. <https://doi.org/10.1016/j.jep.2005.06.004>
- CARVALHO, N. C. et al. Analysis of Aloe vera cytotoxicity and genotoxicity associated with endodontic medication and laser photobiomodulation. **Journal of Photochemistry and Photobiology B: Biology**, v. 178, n. November 2017, p. 348–354, 2018. <https://doi.org/10.1016/j.jphotobiol.2017.11.027>
- CHAMI, N. et al. Antifungal treatment with carvacrol and eugenol of oral candidiasis in immunosuppressed rats. **Brazilian Journal of Infectious Diseases**, v. 8, n. 3, p. 217–226, 2004. <https://doi.org/10.1590/S1413-86702004000300005>
- CHEN, F. M.; LIU, X. Advancing biomaterials of human origin for tissue engineering. **Progress in Polymer Science**, v. 53, p. 86–168, 2016. <https://doi.org/10.1016/j.progpolymsci.2015.02.004>
- CHILDS, D. R.; MURTHY, A. S. Overview of wound healing and management. **Surgical Clinics of North America**, v. 97, n. 1, p. 189–207, 2017. <https://doi.org/10.1016/j.suc.2016.08.013>
- DEVARAJ, S.; JAGANNATHAN, N.; NEELAKANTAN, P. Antibiofilm efficacy of photoactivated curcumin, triple and double antibiotic paste, 2% chlorhexidine and calcium hydroxide against *Enterococcus faecalis* in vitro. **Scientific Reports**, v. 6, n. 1, p. 24797, 21 jul. 2016. <https://doi.org/10.1038/srep24797>
- DHARIWAL, N. et al. A comparative evaluation of antibacterial effectiveness of sodium hypochlorite, Curcuma longa, and Camellia sinensis as irrigating solutions on isolated anaerobic bacteria from infected primary teeth. **Journal of Indian Society of Pedodontics and Preventive Dentistry**, v. 34, n. 2, p. 165, 2016. <https://doi.org/10.4103/0970-4388.180447>
- FARIAS, M. P. et al. Assessment of intracanal medications cytotoxicity ON L929 fibroblast cells | Avaliação da citotoxicidade de medicamentos intracanaais em fibroblastos L929. **Bioscience Journal**, v. 32, n. 2, p. 566–573, 2016. <https://doi.org/10.14393/BJ-v32n2a2016-30974>
- FIRIO, F. B. et al. Effect of incoherent LED radiation on third-degree burning wounds in rats. **Journal of Cosmetic and Laser Therapy**, v. 13, n. 6, p. 315–322, 2011. <https://doi.org/10.3109/14764172.2011.630082>
- GUIMARÃES, A. G. et al. Carvacrol attenuates mechanical hypernociception and inflammatory response. **Naunyn-Schmiedeberg's Archives of Pharmacology**, v. 385, n. 3, p. 253–263, 2012. <https://doi.org/10.1007/s00210-011-0715-x>
- IPEK, E. et al. Genotoxicity and antigenotoxicity of Origanum oil and carvacrol evaluated by Ames Salmonella/microsomal test. **Food Chemistry**, v. 93, n. 3, p. 551–556, 2005. <https://doi.org/10.1016/j.foodchem.2004.12.034>
- KARKARE, S. R.; AHIRE, N. P.; KHEDKAR, S. U. Comparative evaluation of antimicrobial activity of hydroalcoholic extract of Aloe vera, garlic, and 5% sodium hypochlorite as root canal irrigants against *Enterococcus faecalis*: An in vitro study. **Journal of the Indian Society of Pedodontics and Preventive Dentistry**, v. 33, n. 4, p. 274–8, 2015. <https://doi.org/10.4103/0970-4388.165658>

KLEIN, G.; RÜBEN, C.; UPMANN, M. Antimicrobial activity of essential oil components against potential food spoilage microorganisms. **Current Microbiology**, v. 67, n. 2, p. 200–208, 2013. <https://doi.org/10.1007/s00284-013-0354-1>

LANDA, P. et al. In vitro anti-inflammatory activity of carvacrol: inhibitory effect on COX-2 catalyzed prostaglandin E2 biosynthesis. **Archives of Pharmacal Research**, v. 32, n. 1, p. 75–78, 2009. <https://doi.org/10.1007/s12272-009-1120-6>

LARAIA, E. M. S. et al. Effect of low-level laser therapy (660 nm) on acute inflammation induced by tenotomy of achilles tendon in rats. **Photochemistry and Photobiology**, v. 88, n. 6, p. 1546–1550, 2012. <https://doi.org/10.1111/j.1751-1097.2012.01179.x>

LIMA, M. D. S. et al. Anti-inflammatory effects of carvacrol: evidence for a key role of interleukin-10. **European Journal of Pharmacology**, v. 699, n. 1–3, p. 112–117, 2013. <https://doi.org/10.1016/j.ejphar.2012.11.040>

LORETI, E. H. et al. Use of laser therapy in the healing process: a literature review. **Photomedicine and Laser Surgery**, v. 33, n. 2, p. 104–116, 2015. <https://doi.org/10.1089/pho.2014.3772>

MA, J. et al. A new noninvasive model to study the effectiveness of dentin disinfection by using confocal laser scanning microscopy. **Journal of Endodontics**, v. 37, n. 10, p. 1380–1385, 2011. <https://doi.org/10.1016/j.joen.2011.06.018>

MATOS, F. DE S. et al. Effect of laser therapy on the inflammatory response induced by endodontic medications implanted into the subcutaneous tissue of rats. **Revista de Odontologia da UNESP**, v. 43, n. 5, p. 343–350, 2014. <https://doi.org/10.1590/rou.2014.055>

MATOS, F. S. et al. Laser phototherapy induces angiogenesis in the periodontal tissue after delayed tooth replantation in rats. **Journal of Clinical and Experimental Dentistry**, v. 10, n. 4, p. e335-340, 2018.

MELO, F. H. C. et al. Antinociceptive activity of carvacrol (5-isopropyl-2-methylphenol) in mice. **Journal of Pharmacy and Pharmacology**, v. 64, n. 12, p. 1722–1729, 2012. <https://doi.org/10.1111/j.2042-7158.2012.01552.x>

NOSRAT, A. et al. The effect of Carvacrol on *Enterococcus faecalis* as a final irrigant archive of SID. **International Endodontic Journal**, v. 4, n. 3, p. 96–100, 2009.

OLIVEIRA, F. S. et al. Effect of low level laser therapy (830 nm) with different therapy regimes on the process of tissue repair in partial lesion calcaneus tendon. **Lasers in Surgery and Medicine**, v. 41, n. 4, p. 271–276, 2009. <https://doi.org/10.1002/lsm.20760>

POSTEN, W. et al. Low-level laser therapy for wound healing: mechanism and efficacy. **Dermatol Surg**, v. 31, n. 3, p. 334–340, 2005. <https://doi.org/10.1097/00042728-200503000-00016>

RIBEIRO, M. A. G. et al. Morphological analysis of second-intention wound healing in rats submitted to 16 J/cm<sup>2</sup> λ 660-nm laser irradiation. **Indian J Dent Res**, v. 20, n. 3, p. 390, 2009. <https://doi.org/10.4103/0970-9290.57360>

ROCHA-JUNIOR, A. M. et al. Modulation of fibroblast proliferation and inflammatory response by low-intensity laser therapy in tissue repair process. **An Bras Dermatol**, v. 81, n. 2, p. 150–6, 2006. <https://doi.org/10.1590/S0365-05962006000200006>

SCOTT, H. J. Histological study of white blood cells and their association with lipodermatosclerosis and venous ulceration. **Br J Surg**, v. 78, n. 2, p. 210–211, 1991. <https://doi.org/10.1002/bjs.1800780226>

SILVEIRA, P. C. L. et al. Effects of low-power laser irradiation (LPLI) at different wavelengths and doses on oxidative stress and fibrogenesis parameters in an animal model of wound healing. **Lasers in Medical Science**, v. 26, n. 1, p. 125–131, 2011. <https://doi.org/10.1007/s10103-010-0839-0>

TONEA, A. et al. Antibacterial and antifungal activity of endodontic intracanal medications. **Clujul medical (1957)**, v. 90, n. 3, p. 344–347, 2017. <https://doi.org/10.15386/cjmed-750>

TORNECK, C. D. Reaction of rat connective tissue to polyethylene tube implants. I. **Oral Surgery, Oral Medicine, Oral Pathology**, v. 21, n. 3, p. 379–387, 1966. [https://doi.org/10.1016/0030-4220\(66\)90077-6](https://doi.org/10.1016/0030-4220(66)90077-6)

VANHOLDER, R. et al. Cyanoacrylate tissue adhesive for closing skin wounds: a double blind randomized comparison with sutures. **Biomaterials**, v. 14, n. 10, p. 737–742, 1993. [https://doi.org/10.1016/0142-9612\(93\)90037-3](https://doi.org/10.1016/0142-9612(93)90037-3)

VELNAR, T.; BAILEY, T.; SMRKOLJ, V. The wound healing process: an overview of the cellular and molecular mechanisms. **Journal of International Medical Research**, v. 37, n. 5, p. 1528–1542, 2009. <https://doi.org/10.1177/147323000903700531>

WAGNER, H.; WIERER, M.; BAUER, R. In vitro inhibition of prostaglandin biosynthesis by essential oils and phenolic compounds. **Planta Med**, v. 3, p. 184–187, 1986. <https://doi.org/10.1055/s-2007-969117>

WILSON, C. E. et al. Clonal diversity in biofilm formation by *Enterococcus faecalis* in response to environmental stress associated with endodontic irrigants and medicaments. **International Endodontic Journal**, v. 48, n. 3, p. 210–219, mar. 2015. <https://doi.org/10.1111/iej.12301>

ZIELINS, E. R. et al. Wound healing : an update. **Regen Med**, v. 9, n. 6, p. 817–830, 2014. <https://doi.org/10.2217/rme.14.54>