

# DIFFERENTIATION OF FACE AND AURICULAR SHAPE RESULTING FROM DIABETES AND HYPERTENSION IN THE ELDERLY

Lorena Andrade NUNES<sup>1</sup> , Cezar Augusto CASOTTI<sup>2</sup> , Edilson Divino de ARAÚJO<sup>3</sup> 

<sup>1</sup> Postgraduate Program in Nursing and Health, Southwest State University of Bahia, Jequié, Bahia, Brazil.

<sup>2</sup> Department of Health, Southwest State University of Bahia, Jequié, Bahia, Brazil.

<sup>3</sup> Department of Biology, Federal University of Sergipe, Aracaju, Sergipe, Brazil.

## Corresponding author:

Lorena Andrade Nunes

Email: lorenunes2@gmail.com

**How to cite:** NUNES, L.A, CASOTTI, C.A. and ARAÚJO, E.D. Differentiation of face and auricular shape resulting from diabetes and hypertension in the elderly. *Bioscience Journal*. 2021, **37**, e37030. <https://doi.org/10.14393/BJ-v37n0a2021-48141>

## Abstract

The prevalence global of noncommunicable chronic diseases as diabetes and hypertension worldwide has been disregarded until recently by policy makers. In addition, these diseases have growing with the aging of the population. This study sought to identify changes in face shape from the frontal and side views in elderly people diagnosed with diabetes and hypertension. 205 individuals were studied, with 60 years or more, from both sexes, with different ethnicities, and cognition intact. With a digital camera, photos were taken of the front and side and based on these images landmarks for measurement were determined. For statistical analysis, ANOVA, Canonical Variates Analysis, Mahalanobis distance and Thin-Plate Spline were realized. Given sexual dimorphism, the sexes were analyzed separately. From the ANOVA, significant differences ( $p < 0.01$ ) for individuals with diabetes, hypertension, and patients with both or neither of the diseases were observed. The groups were separated by the Canonical Variates and Mahalanobis distance and independent of edentulism, sex or ethnicity. A morphofacial characteristics for the front and side views (especially in the ear region) that identified individuals with these chronic diseases was observed. This methodology can contribute in a specific manner to the identification of at risk populations and help to promote preventative measures for these conditions.

**Keywords:** Anthropometry. Chronic Disease. Ear. Health Risk.

## 1. Introduction

Diabetes Mellitus (DM) and systemic arterial hypertension (SAH) are encountered all over the world and the occurrence of these pathologies tends to increase with age. Additionally, these non-transmittable chronic diseases have been one of the main causes of mortality around the world (Cruzera et al. 1998, Bortoluz et al. 2016). The number of people who present these conditions has increased due to population growth, aging, urbanization, and a growing prevalence of obesity and sedentary lifestyle (Godoy-Matos et al. 2010), being considered a public health concern due to their risk and difficulty to control (Brito et al. 2011, Bortoluz et al. 2016).

However, when there is an early diagnosis of DM and SAH, there are multiple ways to avoid the resulting complications, as well as the possibility of slowing the existing complications and their resultant losses (Brasil 2001). Individuals who have SAH present changes in the face, which frequently presents a rounder character (DBH VI 2010; Oigman 2014). The use of new techniques and knowledge can lead to a better understanding, evening permitting an understanding of the role of the environment and lifestyle (Oliveira and Milech 2006).

Therefore, anthropometry, a common tool in clinical and taxonomic practices has gained significant importance as a public health measure, keeping in mind that it can be used as a biomarker, which is fundamental in the search for prevention, cure or at least intervention in the progress of these diseases (Fjell and Walhovd 2011). Seeking to obtain a more robust analysis, at the start of the 1990s, geometric morphometrics emerged using graphic tools that quantified and permitted the visualization of morphological variations (Adams et al. 2013) allowing better results in comparison with conventional morphometry. The fundamental difference between these was the development of statistical methods used to separately evaluate the variation in the shape of a structure based on the use of landmarks.

In biomedical and/or biological research, the analysis of shape and size of the organs or organism is more precise when using landmarks (Ercan et al. 2012). In medicine, the geometrical properties of the organs are associated with diverse studies based on statistical analyses using qualitative and quantitative measures especially with images (Sigirli and Ercan 2013).

This methodology has been used in diverse health care areas by numerous researchers (Fjell and Walhovd 2011; Khodair et al. 2014; Prasad et al. 2015; Mayer et al. 2017). These studies, however, have principally been developed in infant/juvenile or adult populations while morphological patterns associated with disease in the elderly have not been assessed. Aging causes morphological, psychological and social changes, and is a slow, progressive and irreversible process (Santos-Filho and Ferreira 2016). Therefore, this study sought to identify changes in facial shape from the front and side views in elderly people diagnosed with diabetes and hypertension.

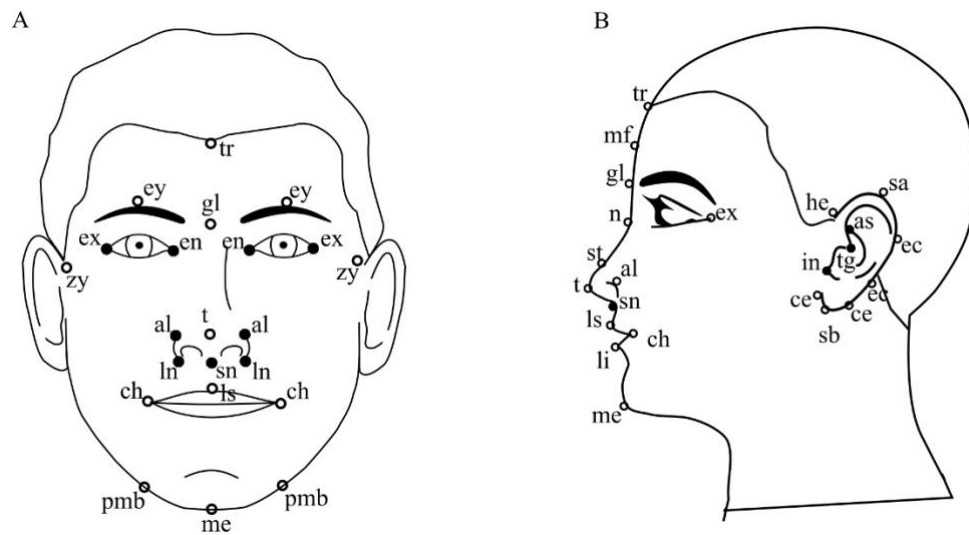
## **2. Material and Methods**

After the submission and approval of the project by the ethics committee (CAAE 56017816.2.0000.0055), individuals with 60 years or more, from both sexes, with cognition intact (Mini-Mental State Examination MMSE) (Folstein et al. 1975) were selected. According to Chinthapalli et al. (2012) neurological and psychiatric diseases can interfere in face shape.

Sampling was realized in 2016 with elderly residents from Aiquara-BA, with a diagnosis for diabetes, hypertension, or both or neither of the diseases. The front and side views of 205 individuals were evaluated, with ages varying from 60 to 95 years. They were photographed using a Canon SX60HS digital camera, at approximately 1.5 m distance, with an identification plaque and a scale bar. None of the participants used glasses. They had a neutral facial expression with their mouth closed, according to the Frankfurt horizontal plane. The men were shaved and the women had their hair behind their ears.

Using the TpsDig2 program (Rohlf 2015), 23 and 22 landmarks and semi-landmarks were placed on the front and side views, respectively (Figure 1). The choice of the points reflected the place where clear characteristics to differentiate between people are visible and that diminish with age. Subsequently, the data was submitted for Procrustes superimposition to remove the effects of scale, rotation and translation. Following the methodology of (Palmer 1994), each individual was measured twice to eliminate the possibility of any errors in the measurement. Finally, the Procrustes ANOVA was realized.

Regression analysis was used to evaluate the allometry effect between the shape and size of the centroid. The interference of edentulism and the effect of sex was evaluated. Following this, the MANOVA, the Canonical Variates Analysis (CVA) of and the Mahalanobis distance using the MorphoJ program (Klingenberg 2011) were realized. Subsequently, the Thin-Plate Spline method was used to graphically verify the variation in shape.



**Figure 1.** Schemes with the location of the landmarks (filled in dots) and semi-landmarks (empty dots) used for the facial differentiation. A – frontal view scheme; and B – side view scheme. Landmarks on the face: Trichion (tr), menton (me), endocanthion (en), exocanthion (ex), cheilion (ch), zygions (zy), alar edge (al), lateral nasal (ln), glabella (gl), nasion (n), çabralo superius (ls) labral inferius (li), tip (t), supretip (st), supra aurale (sa), helix (he), tragus (tg), subaurale (sb), midpoint of the forehead (mf), eyebrow (ey), protrusion of the mental tubercle (pmb), antihelix start (as), intertragic notch (in), Contour of the earlobe (ce), Ear contour (ec).

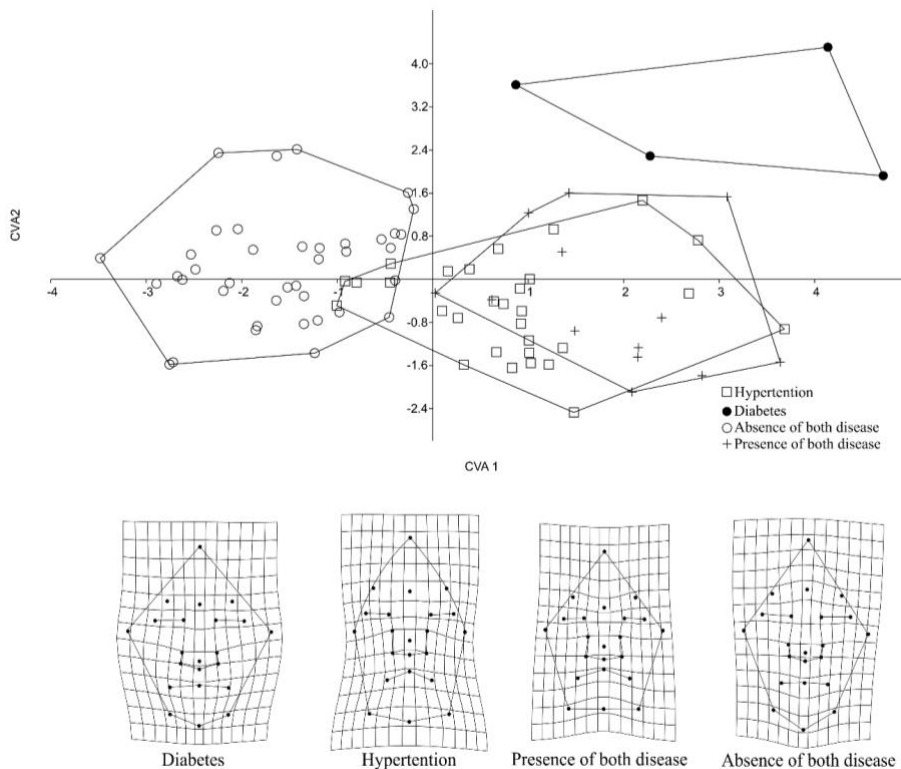
### 3. Results

In the elderly, there are no significant differences ( $p < 0.05$ ) for edentulism in the front and side views. Men and women were evaluated separately due to sexual dimorphism ( $p < 0.01$ ). Subsequently, the effect of allometry was removed using regression. This allometric effect could be due to the natural aging process where gradual and progressive changes to the facial phenotype occur (Santos-Filho and Ferreira 2016).

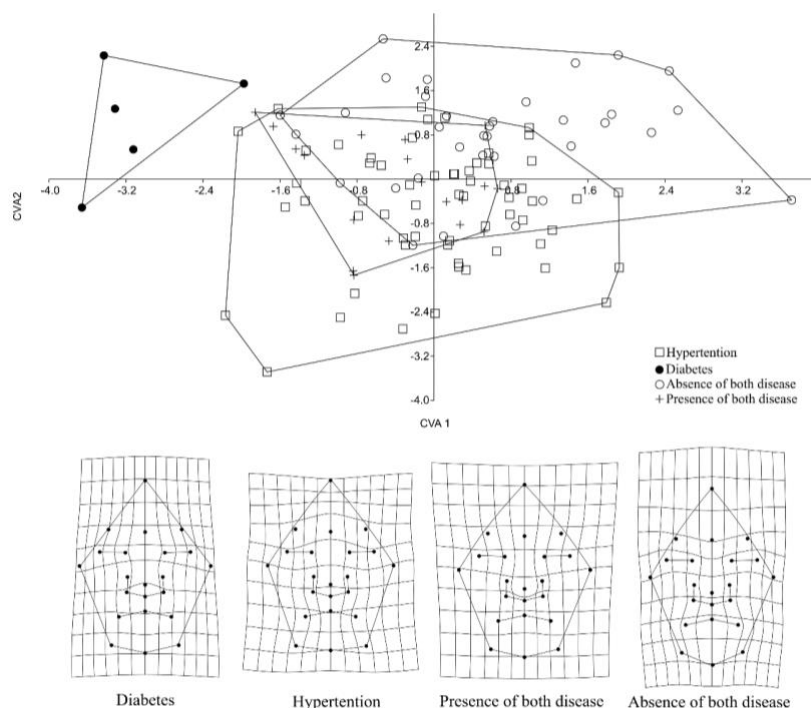
For the frontal view, significant results ( $P < 0.01$ ) were observed in men using the MANOVA. The first two CVA explained 92% of the total variation in the data analyzed. The first CVA explains 70.3% of the variation and differences between the individuals without diabetes and hypertension were observed located on the negative axis of the CVA1 and with both diseases on the positive axis. The following CVA explains 21.7% of the variation and it was possible to separate the diabetic patients from the hypertensive patients. Using the Thin-Plate Splines, the elderly patients with diabetes presented a wider zygomatic arch, while those with hypertension presented a widening in the menton and nasal regions (Figure 2). Those with both diseases, presented a combination of the aforementioned characteristics and those with neither of the diseases had a longer face.

For the Mahalanobis distance, it was possible to observe these differences ( $p < 0.01$ ) with 10,000 replications. There is no significant difference between the frontal shape of the face in individuals with hypertension and diabetes in comparison with those who only have hypertension. The greatest values of dissimilarity, were between the elderly who did not have either disease and those who presented DM.

Amongst women, significant differences were also found using MANOVA ( $p < 0.01$ ). It was found that the first two Canonical Variates explained 82.8% of the total variation. The first CVA explained 49.1% of the variation of the shape of the face due to these chronic diseases and the second explained 33.7%. In a similar manner to that found in the men, using the Thin-Plate Splines, elderly women with diabetes presented a broader zygomatic arch, the hypertensive female patients presented a broader menton and nasal region, while those with both diseases presented a combination of the prior characteristics. Those with neither disease showed a longer face (Figure 3).



**Figure 2.** Dispersion graph related to the analysis of the main components for the frontal view in men and Thin-Plate Spline related to each analyzed group.

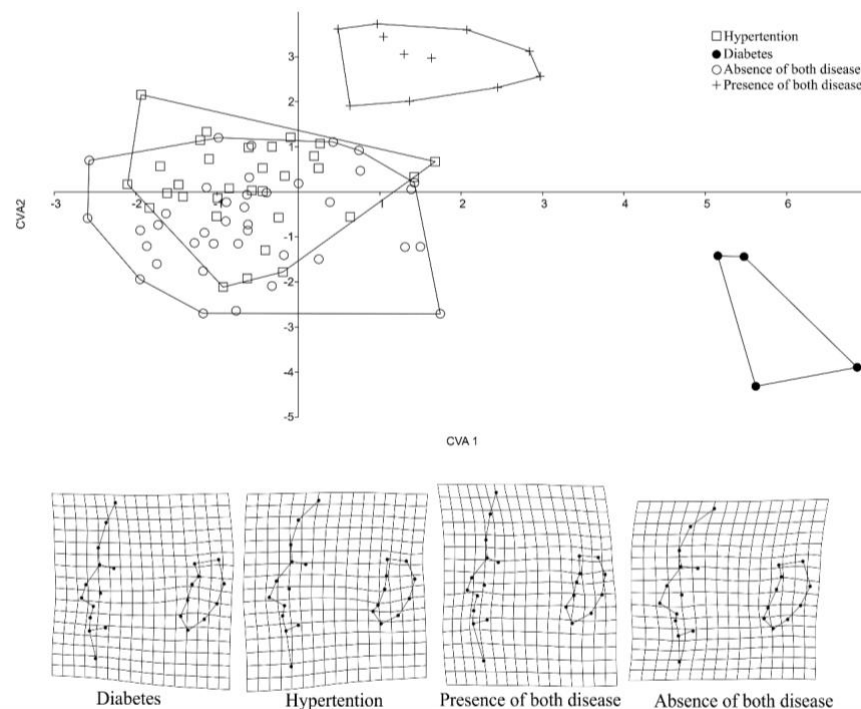


**Figure 3.** Dispersion graph related to the analysis of the main components for the frontal view in women and Thin-Plate Spline referent to each group analyzed.

Based on the Mahalanobis distance, significant differences ( $p < 0.01$ ) were found with 10,000 replications. In a manner similar to the elderly men, significant differences between those with both diseases and those with SAH were not encountered. The highest values for dissimilarity were between the elderly women who did not have both diseases with those who presented DM.

When analyzing the side view of the men, the MANOVA presented significant results ( $p < 0.01$ ). The first two CVA explained 84% of the variation, with 50% and 34% in the first and second variables respectively. For the Thin-Plate Splines, the elderly men with diabetes were identified, presenting widening in the upper region of the ear, narrowing between the antihelix start and the curve of the ear, as well as a longer earlobe

region. In hypertensive men, the side point of the nasal ala is wider in relation to the internal point between the tip of the nose and the upper lip, having a wider chin, and generally presenting a smaller pinna as well. Similar to the frontal view, those who presented both diseases had a combination of the characteristics noted above (Figure 4). The elderly men who presented neither disease, had a shorter region of the menton and the internal point between the tip of the nose and the upper lip and a widening of the auricular curve from the antihelix start in relation to the intertragal notch.



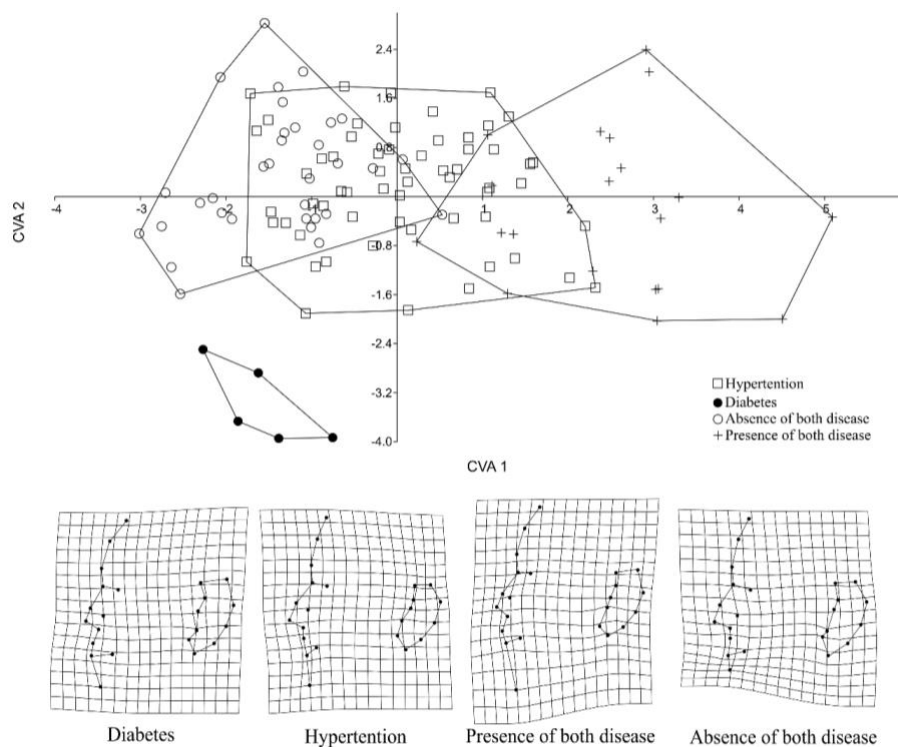
**Figure 4.** Dispersion graph referent to the analysis of the main components for the side view in men and Thin-Plate Spline referent to each group analyzed.

Using the Mahalanobis distance, significant differences ( $p < 0.01$ ) were found between men, for the side view between all the groups analyzed with 10,000 replications. The greatest dissimilarity was between those who presented both diseases with those who only presented DM. The least similarity was observed between those who presented neither disease and those with SAH.

For the women, the first two CVA grouped together 78.5% of the total variation, with the first CVA explained by 56.4% of the variation and the second by 22.1%. Elderly diabetic women, similar to the men, presented widening in the upper region of the curve of the ear and a longer, narrower earlobe. In the hypertensive women, the nasal ala was broader in relation to the internal point between the tip of the nose and the upper lip, a broader chin and a smaller pinna. Those who presented both diseases showed a combination of characteristics. Those who presented neither disease, showed a shorter region of the menton and the internal point between the tip of the nose and the upper lip, a shorter curve of the earlobe in the anterior region and a widening of the auricular curve from the antihelix start in relation to the intertragal notch (Figure 5).

From the side view, as was observed in the men, the Mahalanobis distance showed significant differences ( $p < 0.01$ ) between all the groups analyzed with 10,000 replications. The greatest dissimilarity was between those who presented both diseases with those who only had DM, and the least similarity was observed between those who presented neither disease with those with SAH.





**Figure 5.** Dispersion graph referent to the analysis of the main components for the side view in women and the Thin-Plate Spline referent to each group analyzed.

#### 4. Discussion

Despite sexual dimorphism, there are morphological patterns for the frontal view, related to the evaluated diseases. For both sexes, the individuals who had hypertension presented a wider menton and nasal region, characterizing a rounder face. This corroborated the observations of other authors (DBH VI 2010; Oigman 2014) who reported hypertensive patients with a rounder face shape as well as indicated the existence of bilateral eyelid swelling.

Elderly people with a diagnosis for diabetes presented a broader zygomatic region than in the other parts of the face. Similar results were found for Demayo et al. (2009) in adults from 18 to 60 years of age, where diabetics presented a wider facial shape. Hyperglycemia creates a predisposition for cellular anomalies that produce changes both in the thickness and elasticity of the skin of approximately 30% of the people with this disease (Ramos 2017). Additionally, diabetes is associated with swelling and an accumulation of bodily fluids between the cells or in bodily cavities (Anwer et al. 2011) that are generally visible especially in the face.

Due to these changes that occur in individuals who are diagnosed with SAH and DM as cited by (DBH VI 2010; Anwer et al. 2011; Oigman 2014), in the elderly with both diseases, independent of sex, the shape of the face presented shape characteristics such as a widening in the zygomatic region and of the menton together. However, those who presented neither disease had a more elongated face shape, results that corroborated with Demayo et al. (2009), in which the individuals that presented diabetes had a longer, more pointed facial shape.

From the side view, what draws our attention is that the greater part of the variation in terms of the diseases is located in the auricular region. This structure is being studied and used with different objectives (Alexander et al. 2011; Zulkifli et al. 2014). It has shown itself to be effective in the diagnosis of diseases and has been widely used in other areas as a reference (Chattopadhyay and Bhatia 2009). The pattern for the morphology of the ear can be changed as a result of the ethnic group, age and sex (Alexander et al. 2011). Additionally, the shape, size and direction of the outer ear is as specific for each individual as the finger print and does not change throughout the life of the individual (Chattopadhyay and Bhatia 2009).

In addition to the reports of anthropologists, regarding the existence of the characteristics and the shape of the outer ear being different in humans (Zulkifli et al. 2014), our study indicates that there is still a relationship between the form of the ear and chronic diseases. Many advantages are associated with the use of the outer ear for identification in humans based on the angle, direction, size and relationships with

the outer ear. Given this, the characteristics of the ear, also known as the auricula, have been applied in forensic science as a valuable characteristic to identify cadavers, based on photographs as well as methods of reconstruction (Zulkifli et al. 2014). The morphology of the ear can help to clarify the question of the individuality of each individual corroborating evidence for identification (Chattopadhyay and Bhatia 2009). Given this, probably the best results for the separation of the groups evaluated as seen using the Mahalanobis distance, was by the side view with this region presenting specific characteristics.

It is also worth noting that, despite the small sample size, diabetic individuals presented differentiated morphological patterns for both sexes and views, highlighting the extent to which this disease interferes in the shape of the face. The reduced sample size for the elderly with diabetes is related to the difficulty to identify elderly people who only have this condition, keeping in mind that normally it is associated with other diseases such as hypertension. The complications for diabetes are associated with hypertension in 35 to 70% of the patients and its prevalence is high, mainly in those patients that have type 1 diabetes (Cruzera et al. 1998). SAH acts in association with other risk factors, including DM (Lolio 1990). As well as the morphological variations, the majority of the patients with both diseases present a higher risk of vascular and macro vascular complications (Anwer et al. 2011). This leads to a greater focus and care with these patients, which is heightened by the fact that these patients are elderly.

Considering the problem of DM and SAH, the monitoring of individuals for early diagnosis, and the whole field of knowledge about these conditions, can offer various ways to avoid complications or at least slowing the progression of those complications that already exist and their associated losses (Brasil 2001). This can be seen with the example of SAH, which can become asymptomatic for a number of years, frequently being considered “the silent killer” (Oigman 2014). DM, has been a serious public health problem and its prevalence, morbidity and mortality have increased. Additionally, it is a disease that can occur across different age brackets (Gomes et al. 2009).

Geometrical morphometrics have been effective to identify the patterns associated with diseases based on the description of the shape of the face and can be used in the identification of specific problems in the health care area (Demayo et al. 2009). The small variations found, in addition to those observed in relation to the diseases for both sexes, are resultant from sexual dimorphism. This has also been found by Schaefer et al. (2004), Demayo et al. (2009), Scott et al. (2010), and Mitteroecker et al. (2015).

In the human face in the elderly, despite sexual dimorphism, ethnicity and facial variations resultant from human aging, there is a morphological pattern both from the frontal view and from the side view, especially in the auricular region, that identifies individuals with a diagnosis of diabetes, hypertension, with both diseases or with neither. It is worth highlighting that according to Zhang et al. (2014), establishing a diagnosis based on the face using quantitative analyses and resources can contribute to the reduction of bias in the identification of diseases. Therefore, methods capable of identifying and realizing an active search for possible carriers of these chronic diseases would significantly contribute to the identification of the at risk population, and therefore, by way of measures promoting and preventing these conditions, would reduce the morbidity and mortality attributed to them.

## 5. Conclusions

The elderly populations with chronic disease show variations in the shape of face front (zygomatic arch, in the menton and nasal regions) and side views (especially in the ear region). Geometric morphometrics is efficient in the categorization in elderly with diabetes hypertension and both diseases. Geometric morphometrics emerged as a promising method to identify health conditions, since it allows identifying them based on face shape factors that indicate chronic diseases.

**Authors' Contributions:** NUNES, L.A.: conception and design, acquisition of data, analysis and interpretation of data, and drafting the article; CASOTTI, C.A.: conception and design, and drafting the article; ARAÚJO, E.D.: analysis and interpretation of data, and critical review of important intellectual content. All authors have read and approved the final version of the manuscript.

**Conflicts of Interest:** The authors declare no conflicts of interest.

**Ethics Approval:** Approved by Research Ethics Committee of Southwest State University of Bahia. CAAE: 56017816.2.0000.0055.

**Acknowledgments:** The authors would like to thank the funding for the realization of this study provided by the Brazilian agency CAPES (Coordenação de Aperfeiçoamento de Pessoal de Nível Superior - Brasil), Finance Code 001.

## References

- ADAMS, D.C., ROHLF, F. J. and SLICE, D.E. A field comes of age: Geometric morphometrics in the 21st century. *Hystrix*. 2013, **24**(1), 7–14. <https://doi.org/10.4404/hystrix-24.1-6283>
- ALEXANDER, K.S., et al. A morphometric study of the human ear. *Journal of Plastic, Reconstructive & Aesthetic Surgery*. 2011, **64**(1), 41–47. <https://doi.org/10.1016/j.bjps.2010.04.005>
- ANWER, Z., et al. Hypertension management in diabetic patients. *European Review for Medical and Pharmacological Sciences*. 2011, **15**, 256–1263.
- BORTOLUZ, S., LIMA, L.A. and NEDEL, F.B. Condições de saúde e utilização de um serviço de atenção primária em pacientes hipertensos e/ou diabéticos. *Ciência & Saúde*, 2016, **9**(3), 156-166. <https://doi.org/10.15448/1983-652X.2016.3.22009>
- BRASIL. Ministério da Saúde. Departamento de Atenção Básica. Área Técnica de Diabetes e Hipertensão Arterial Hipertensão arterial sistêmica (HAS) e Diabetes mellitus (DM): protocolo /Ministério da Saúde, Departamento de Atenção Básica. Área Técnica de Diabetes e Hipertensão Arterial. – Brasília: Ministério da Saúde, 2001. 96 p. il. (Cadernos de atenção Básica, 7)
- BRITO, E.S., PANTAROTTO, R.F.R. and COSTA, L.R.L.G. A hipertensão arterial sistêmica como fator de risco ao acidente vascular encefálico (AVE). *Nursing*. 2011, **29**(4), 265–268.
- CHATTOPADHYAY, P.K. and BHATIA, S. Morphological examination of ear: A study of an Indian population. *Legal Medicine*. 2009, **11**(1), S190–S193. <http://dx.doi.org/10.1016/j.legalmed.2009.02.057>
- CHINTHAPALLI, K., et al. Atypical face shape and genomic structural variants in epilepsy. *Brain*. 2012, **135**(10), 3101–3114. <https://doi.org/10.1093/brain/aws232>
- CRUZERA, A.B., UTIMURA, R. and ZATZ, R.A hipertensão no diabete. *HiperAtivo*. 1988, **5**(10), 261–266.
- DBH. VI Diretrizes Bras Hipertens - Sociedade Brasileira de Cardiologia [Internet]. 2010, **95**, 1–51. Available from: [http://bvsms.saude.gov.br/bvs/publicacoes/caderno\\_atencao\\_basica\\_n1\\_p1.pdf](http://bvsms.saude.gov.br/bvs/publicacoes/caderno_atencao_basica_n1_p1.pdf). Access in: 27 abr. 2017
- DEMAYO, C.G., TORRES, M. and VEÑA, C. Face Shapes Of Diabetics And Non-Diabetics Described Using Geometric Morphometrics. *The Internet Journal of Endocrinology*. 2009, **6**(1), 1–10.
- ERCAN, I., et al. Statistical Shape Analysis and Usage in Medical Sciences : Review. *Turkiye Klinikleri Journal of Biostatistics*. 2012, **4**(1), 27-35.
- FJELL, A.M. and WALHOVD, K.B. New Tools for the Study of Alzheimer’s Disease: What Are Biomarkers and Morphometric Markers Teaching Us? *Neuroscientist*. 2011, **17**(5), 592–605. <https://doi.org/10.1177/1073858410392586>
- FOLSTEIN, M.F., FOLSTEIN, S.E. and MCHUGH, P.R. "Mini-mental state". A practical method for grading the cognitive state of patients for the clinician. *Journal of Psychiatric Research*. 1975, **12**(3), 189-98. [https://doi.org/10.1016/0022-3956\(75\)90026-6](https://doi.org/10.1016/0022-3956(75)90026-6)
- GODOY-MATOS, A.F., et al. Adiponectin is related to intramyocellular lipid content in non-diabetic adults. *Journal of Endocrinological Investigation*. 2010, **33**(6), 382-7. <https://doi.org/10.1007/BF03346608>
- GOMES, M.B. and COBAS, R. Diabetes Mellitus. In: GROSSI, S.A.A., PASCALI, P.M. (Eds.). *Cuidados de Enfermagem em Diabetes Mellitus*. São Paulo: Sociedade brasileira de diabetes, 2009.
- KHODAIR, S.A., GHIEDA, U.E. and ELTOMEY, M.A. Relationship of lumbosacral spine morphometrics and lumbar disc degenerative disease in young adults using magnetic resonance imaging. *The Egyptian Journal of Radiology and Nuclear Medicine*. 2014, **45**(2), 461–466. <https://doi.org/10.1016/j.ejnm.2014.02.005>
- KLINGENBERG, C.P. MorphoJ: In integrated software package for geometric morphometrics. *Molecular Ecology Resources*. 2011, **11**(2), 353–357. <https://doi.org/10.1111/j.1755-0998.2010.02924.x>
- LOLIO, C.A. Epidemiologia da hipertensão arterial. *Revista de Saúde Pública*, 1990, **24**(5), 425–432. <https://doi.org/10.1371/journal.pone.0169336>
- MAYER, C., et al. BMI and WHR are reflected in female facial shape and texture: A geometric morphometric image analysis. *PLoS ONE*. 2017, **12**(1), 1–13. <https://doi.org/10.1371/journal.pone.0172205>
- MITTEROECKER, P., et al. The Morphometrics of “Masculinity” in Human Faces. *PLoS ONE*. 2015, **10**(2), e0118374. <https://doi.org/10.1371/journal.pone.0118374>
- OIGMAN, W. Sinais e Sintomas em hipertensão arterial. *Journal of Biological Methods*. 2014, 13–18. <http://files.bvs.br/upload/S/0047-2077/2014/v102n5/a4503.pdf>
- OLIVEIRA, J.E.P. and MILECH, A. *Diabetes Mellitus - Clínica, Diagnóstico e Tratamento Multidisciplinar*. 1<sup>st</sup> ed. São Paulo: Atheneu, 2006.
- PALMER, A.R. Fluctuating asymmetry analyses: A primer. In: Markow, T.A (Ed). *Developmental Instability: Its Origins and Evolutionary Implications*. Netherlands: Kluwer Academic Publishers, 1994. [https://doi.org/10.1007/978-94-011-0830-0\\_26](https://doi.org/10.1007/978-94-011-0830-0_26)



PRASAD, S., et al. Craniofacial Dysmorphology in 22q11.2 Deletion Syndrome by 3D Laser Surface Imaging and Geometric Morphometrics: Illuminating the Developmental Relationship to Risk for Psychosis. *American Journal of Medical Genetics*. 2015, **167A**(3), 529-536.

<https://doi.org/10.1002/ajmg.a.36893>

RAMOS, A. *Manifestações dermatológicas do Diabetes*. 2017. Available from: <http://www.diabetes.org.br/ebook/component/k2/item/45-manifestacoes-dermatologicas-do-diabetes>

ROHLF, F. J. tpsDig2 Version 2.22. *Ecology & Evolution*. SUNY at Stony Brook. 2015

SANTOS-FILHO, E.F. and PEREIRA, H.B.B. O envelhecimento facial humano e sua mensuração – o passo inicial da prosoporreconografia. *Revista Sodebras*. 2016, **11**, 67-71.

SCHAEFER, K., et al. Craniofacial Dimorphism Patterns and Allometry among Hominoids. *Annals of Anatomy*. 2004, **186**(5–6), 471–478.

[https://doi.org/10.1016/S0940-9602\(04\)80086-4](https://doi.org/10.1016/S0940-9602(04)80086-4)

SCOTT, I.M.L., et al. Does masculinity matter? The contribution of masculine face shape to male attractiveness in humans. *PLoS ONE*. 2010, **5**(10), 23–27. <https://doi.org/10.1371/journal.pone.0013585>

SIGIRLI, D. and ERCAN, I. Growth and Allometry in Modern Morphometrics: Review. *Turkiye Klinikleri Journal of Biostatistics*. 2013, **5**(1), 42-48.

ZHANG, B., VIJAYA KUMAR, B.V.K. and ZHANG, D. Noninvasive diabetes mellitus detection using facial block color with a sparse representation classifier. *IEEE Transactions on Biomedical Engineering*. 2014, **61**(4), 1027–1033. <https://doi.org/10.1109/TBME.2013.2292936>

ZULKIFLI, N., YUSOF, F.Z. and RASHID, R.A. Anthropometric Comparison of Cross-Sectional External Ear between Monozygotic Twin. *Annals of Forensic Research and Analysis*. 2014, **1**(2) 2–7.

**Received:** 14 April 2019 | **Accepted:** 14 April 2021 | **Published:** 12 June 2021



This is an Open Access article distributed under the terms of the Creative Commons Attribution License, which permits unrestricted use, distribution, and reproduction in any medium, provided the original work is properly cited.